



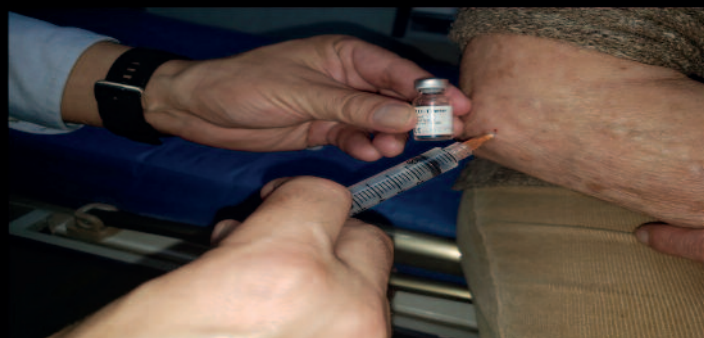EPICONDYLITIS – A SOLUTION WITH COLLAGEN MEDICAL DEVICES

HOW TO VALIDATE COLLAGEN MDs AS A THERAPEUTIC OPTION

- THE KEY IS AN EFFICIENT IMAGING AND CLINICAL DIAGNOSTIC;
OTHERWISE YOU DISCREDIT THE VALUE OF THERAPY AND YOURSELF
- THERE IS NO MAGICAL HEALING THERAPY
- SCIENTIFIC STUDIES TO PROVE THE USEFULNESS OF THE COLLAGEN MDs TO THE
MEDICAL COMMUNITY

HOW TO VALIDATE COLLAGEN MDs AS A THERAPEUTIC OPTION

- THE INFILTRATION TECHNIQUE IS LEARNED EASILY, IT IS EASILY REPRODUCED
WITHOUT COMPLICATIONS IF YOU KNOW SUPERFICIAL AND DEEP ANATOMY



EPICONDYLITIS, WHAT'S ON

- IT IS FREQUENTLY ASKED BY PATIENTS
- IT IS RECURRENT
- SELF LIMITED IN 12 OR MORE MONTHS
- 20% OF EPICONDYLITIS ARE SECONDARY
- IT IS OPERATED IN NO MORE THAN 5% OF THE CASES
- TOO MANY TREATMENTS EXIST; IT IS A PROBLEM THAT DOES NOT KILL BUT IT IS EXTREMELY ANNOYING

LET'S THINK

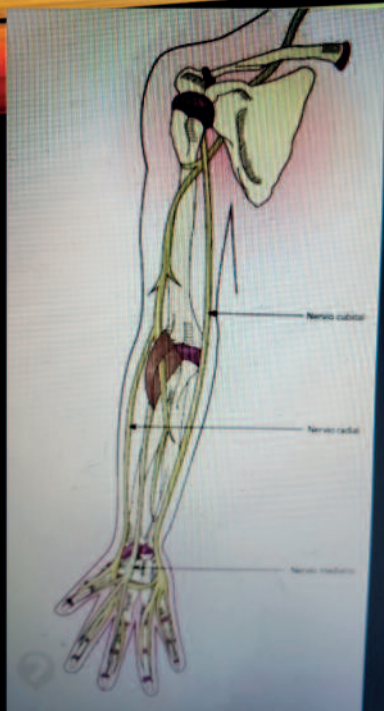
- THE ELBOW IS A BIOMECHANICAL POINT OF STRESS OF THE UPPER LIMB
- IF WE CONSIDER IT AS A LEVER, IT RECEIVES STRENGTH FROM ITS TWO OPPOSITE EXTREMES AND IT MUST REGULATE AND DISPERSE IT FOR THE CORRECT BALANCE OF THE FUNCTION TO BE PERFORMED

ANATOMY

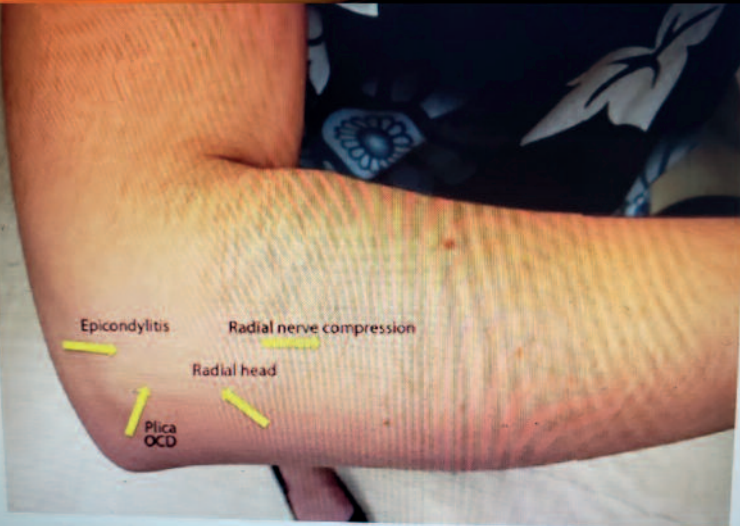

Fig. 3 Location of the site of greatest tenderness may be helpful in defining the diagnosis for further clinical testing and/or imaging techniques.

NEUROANATOMY

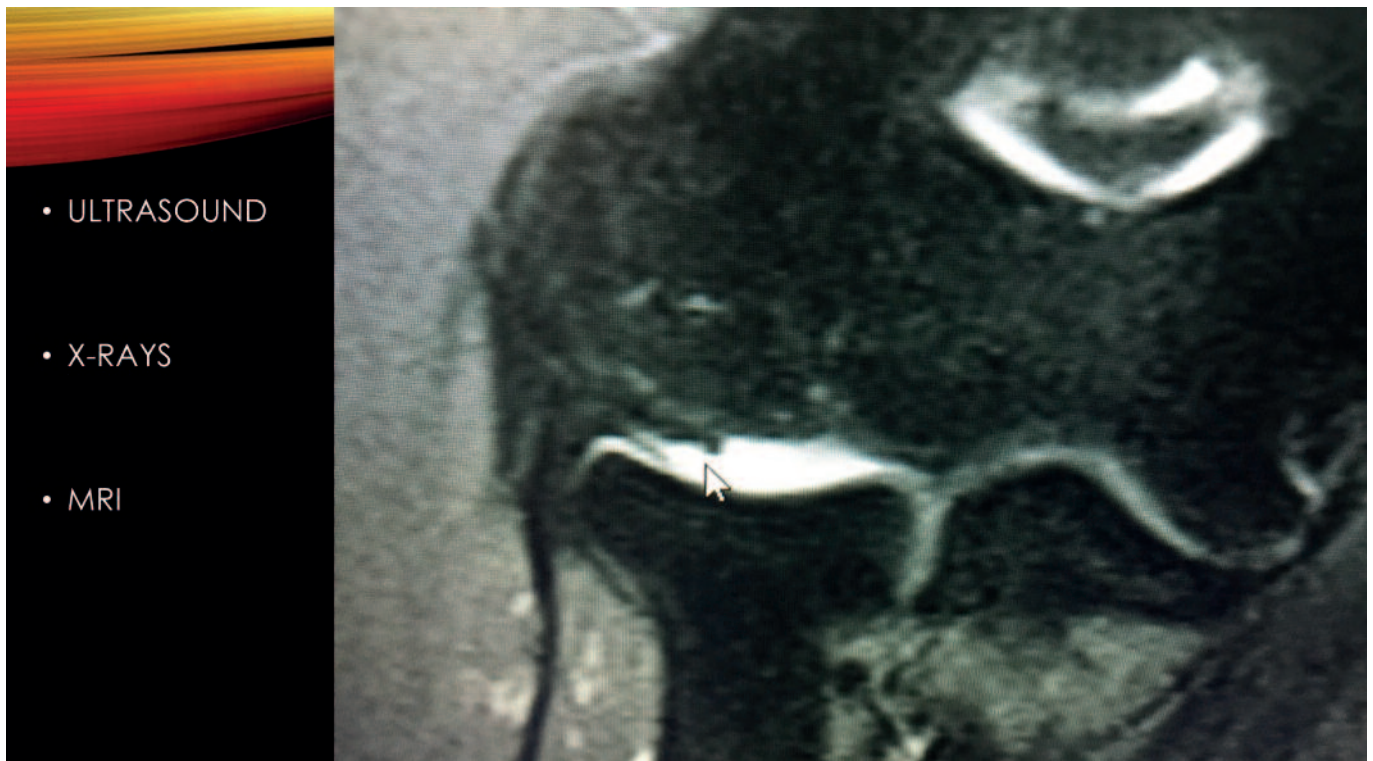


PRIMARY EPICONDYLITIS

- TENDINOSIS
- MUSCLE TEARING

SECONDARY EPICONDYLITIS

- SD RADIAL NERVE TUNNEL
- SD ULNAR NERVE TUNNEL
 - THESE ARE THE KEYS
- JOINT DAMAGE, OSTEOCHONDritis, ARTHRITIS
- SWELLING
- THE PRESENCE OF DEGENERATIVE TISSUE IN THE RADIOCAPITELLAR JOINT



WHY SO MANY RECURRENT CASES FOR SOMETHING SO LOCAL AND SIMPLE?

- MANY THERAPIES BUT TOO MANY FAILURES
- POOR DIAGNOSIS
- POOR STUDY OF THE DISEASE
- BIO-PSYCHO-SOCIAL RELATIONS

WHY COLLAGEN MDs?

- WHY NOT?
 - IT IS SIMPLE
 - BIOLOGICAL
 - GOOD PRICE/QUALITY RATIO

COLLAGEN MDs

- SO FAR NO COMPLICATION AFTER 5 YEARS OF USE
- IT WORKS, IT REORGANIZES AND REGENERATES COLLAGEN:
IT HAS A STRONG SCIENTIFIC SUPPORT
- THE KEY IS TO HAVE CONCISE CLINICAL EVALUATIONS, GOOD PATIENTS
AND TO DO A GOOD FOLLOW-UP
- WITH TRUST YOU GET A BIGGER SCIENTIFIC FOUNDATION AND THE WELL-
BEING OF YOUR PATIENTS

RESULTS OF PARTIAL FOLLOW-UPS

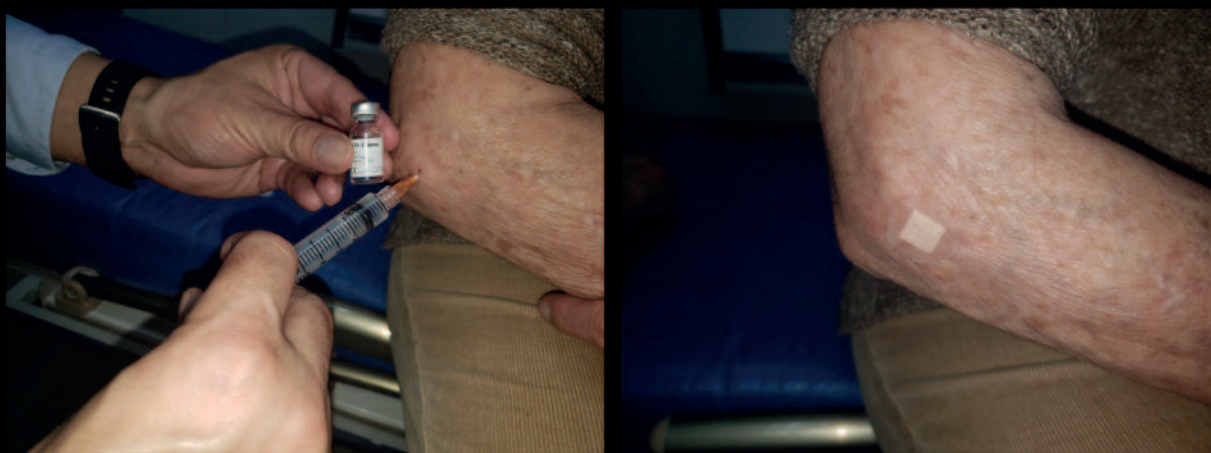- ACTIVE PATIENTS
- DISCARDING OF PREVIOUS INEFFECTIVE TREATMENT
- MOST PEOPLE CHOOSE TO DO AN ULTRASOUND
- 98% RECOVERY RATE WHEN ADMINISTERING BETWEEN 4 AND 6 DOSAGES

PARTIAL RESULTS

- 15 PATIENTS TREATED FOR EPICONDYLITIS
- MOST PATIENTS ARE POLICEMEN
- 5 CIVILIANS
- 2 SPORTSPEOPLE

EPICONDYLITIS

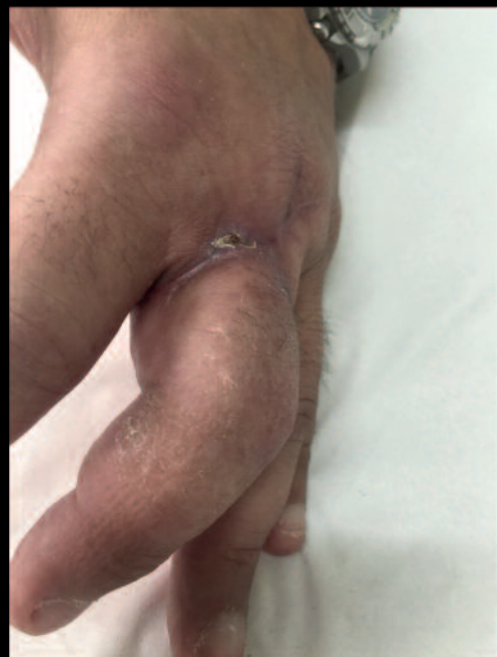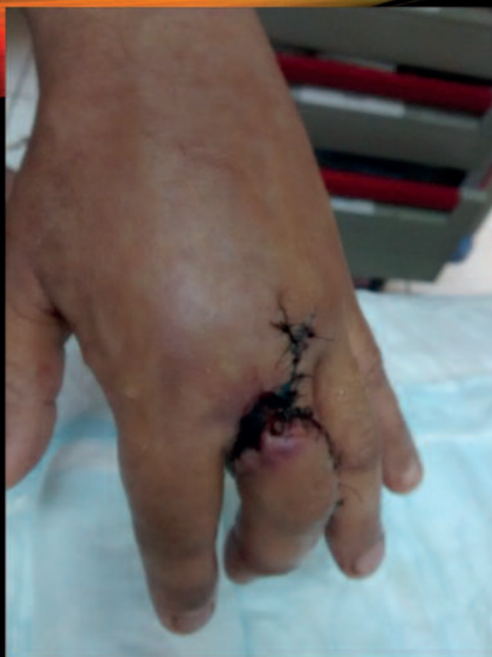- 90% HEALED AFTER 2 MONTHS AND 6 SHOTS IN SIX MEETINGS
- INFILTRATIONS ACCORDING TO THE DIAGNOSE, PURE OR WITH DEGENERATIVE TISSUE INSIDE THE JOINT
- I PREFER THE USAGE OF MD-TISSUE

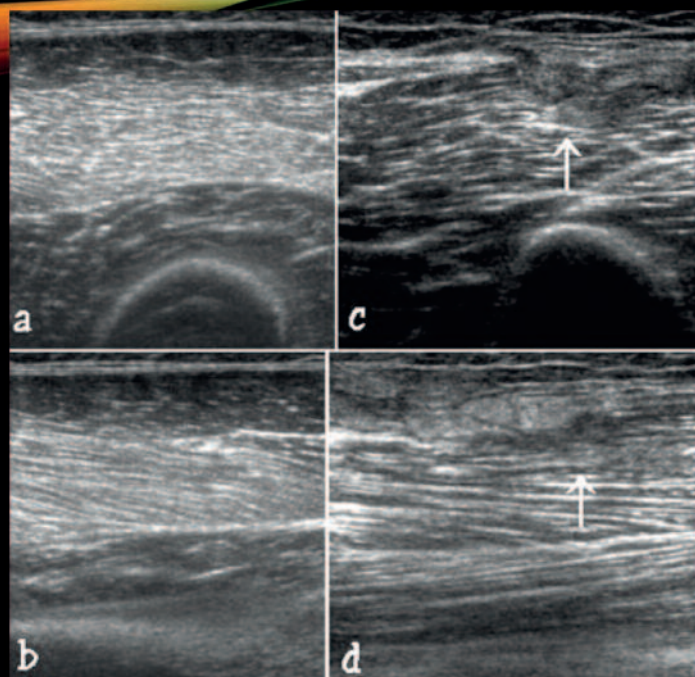
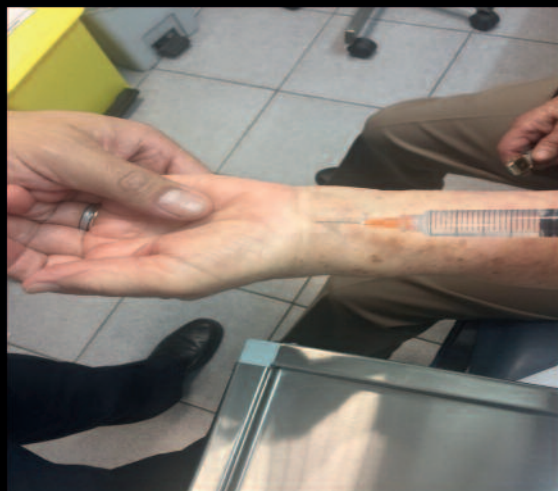
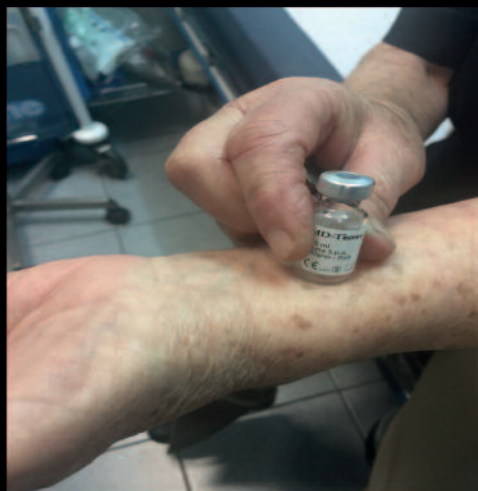
COLLAGEN MDs

I HAVE TREATED:

- ARTHRITIS
- TEARINGS
- TENDINITIS
- SPRAINS
- CARPAL TUNNEL SYNDROME
- TENOSYNOVITIS OF QUERVAIN
- SYNOVIAL CYSTS
- SCARS





BIBLIOGRAPHY

- BONE JOINT J 2013;95-B:1158-64
- EFORT OPEN REV 2016 ; 1:391-397

Paper presented at the
2nd INTERNATIONAL CONGRESS
"COLLAGEN IN THE PATHOLOGIES OF
THE MUSCULO-SKELETAL APPARATUS
- Painful diseases of Joint & Muscle System.
Important contribution of Collagen Medical
Devices"
Milan, 16th November 2019

author

Oscar Ahumada Arredondo, MD
– University of Chile
Hospital de Carabineros
Santiago, Chile