



E. Milano



## SUMMARY

Spondylolisthesis is a mechanical alteration in the physiological vertebral structure that is primarily characterised by the forward displacement of a part of or whole vertebra on to that below.

The L-S rachis segment is mostly interested.

There are 3 kinds of Spondylolisthesis: dysplastic, due to osteo-articular congenital alterations; isthmic, characterized by a continuous lesion of the isthmus; degenerative.

– The aim of this study is to verify if a combined treatment, Physiokinesitherapy + ultrasound-guided injection of Collagen MD (Medical Device)-Lumbar, may provide more important and durable clinical results rather than Physiokinesitherapy alone.

– 20 patients, F and M, aged between 40 and 75, have been enrolled; all of them suffering from grade 1 and 2 Spondylolisthesis.

They were randomised to 2 Groups (10 + 10 patients), a treated Group (T) and a control Group (NT).

– The clinical results, evaluated at 2, 4, 8 and 12 months with the Numeric Rating Scale, the Oswestry Disability Index, the Pain Disability Index and the use of NSAIDs (number of tablets/week), allow to state that the combined treatment Physiokinesitherapy + MD-Lumbar obtains a far better and longer-lasting improvement than Physiokinesitherapy alone.

## KEY WORDS

SPONDYLOLISTHESIS, MEDICAL DEVICE LUMBAR, COLLAGEN, ARTHROSIS

## COLLAGEN MEDICAL DEVICE LUMBAR IN THE COMBINED TREATMENT OF LUMBAR INSTABILITY-INDUCED PAIN

## INTRODUCTION

**Spondylolisthesis (SL)** [from the Greek *spóndilos* (vertebra) and *ólítesis* (slipping)] is a mechanical alteration in the physiological vertebral structure that is primarily characterised by the **forward displacement** (anterolisthesis) of a part of or whole vertebra onto that below.

– Although SL can affect any segment of the spine, it is the lumbar segment that is most commonly affected.

Various authors have estimated the incidence of SL in the general population to be 3-8%; however, it can affect up to

20% of the individuals involved in occupational activities or sports requiring hyperlordosis (e.g. artistic gymnastics, gymnastic rings, diving, golf) or in the handling of heavy loads (e.g. weightlifting).

– Clinicians are often called on to identify the origin of spinal pain and equally frequently forget that even a moderate spinal microinstability, such as SL, may be the cause.

One particularly important anatomical point in SL is the vertebral isthmus, the element between the superior and inferior apophyses that forms a connection

between the anterior and posterior portion of the vertebra.

Undoubtedly, one of the least resistant points of the spine is the **lumbosacral junction (L5-S1)**, where the slope of the upper surface of S1 tends to cause the body of L1 to slip downwards and forwards.

– This displacement is restricted by the anatomical connections of the posterior arch of L5 and, in particular, by the isthmus.

– SL occurs when the isthmus is subject to interruption or destruction.

Furthermore, in addition to the osteoarticular structures, whose focal point are the spinal facet joints, seat to inflammatory processes developed over time driven by the pro-inflammatory cytokine network, the tendinous and ligamentous structures (e.g. the yellow ligament), the capsular structures, the intervertebral disc, the muscle structures (the multifidus muscle and the iliopsoas muscle) and the deep *fasciae* structures are also involved in the origin of SL-induced pain (mechanical low back pain).

- There are 3 main types of SL:

### DYSPLASTIC

The dysplastic form is secondary to congenital osteocartilaginous alterations in the isthmus and consists of 2 main subtypes:

**1)** the form that is secondary to the sagittal orientation of the articular apophyses of S1 that lose contact with L5, which therefore slips forward;

**2)** the form that is secondary to the pathological elongation of the isthmus of L5.

### ISTHMIC

In most cases (**80%**), idiopathic bilateral isthmus lysis involves L5 and it is characterised by a fracture of the isthmus, which causes an increase in the size of the spinal canal, as the posterior portion remains in place

The inter-articular portion (i.e. isthmus) is the point of least resistance subject to continuous microtraumas that, together with other environmental and genetic factors, reduce its mechanical resilience.

– During development, isthmus SL often occurs following a minor trauma, thus revealing the underlying malformation.

The signs and symptoms differ from those observed in adults; young patients experience mild pain without any specific topographical location, even in the presence of significant anterior displacement.

– In some cases, the only sign is hypertonia of the posterior thigh muscles, making it difficult to flex the limb at the hip with the knee extended.

### DEGENERATIVE

The degenerative form is very common and is often little considered, partly due to the minimal likelihood of efficacious treatment, which constitutes the **target of this study**.

– Unlike isthmus SL, the degenerative form causes a reduction in the dimensions of the spinal canal; the favouring factors are the degeneration of the disc and of the articular apophyses, and an excessively vertical orientation of the articular apophyses.

In addition to low back pain, it can also be associated with neurogenic claudication caused by spinal canal stenosis.

Degenerative SL affects adults; it is caused by long-standing spinal instability and by alterations secondary to the abnormal displacement of the unstable segments, i.e. **osteoarthritis** and/or **degenerative disc disease**.

This form is **4-6** times more common in **females** and affects L4 10 times more frequently; the anterior displacement can be up as much as 33%.

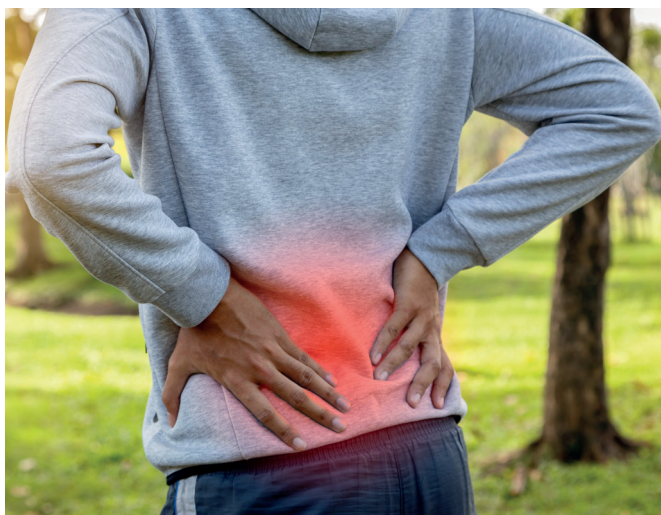The degree of displacement is primarily assessed using the Meyerding Grading System, which classifies it into 4 grades: in grade **1**, the displacement is equal to less than 25% of the upper surface of S1;

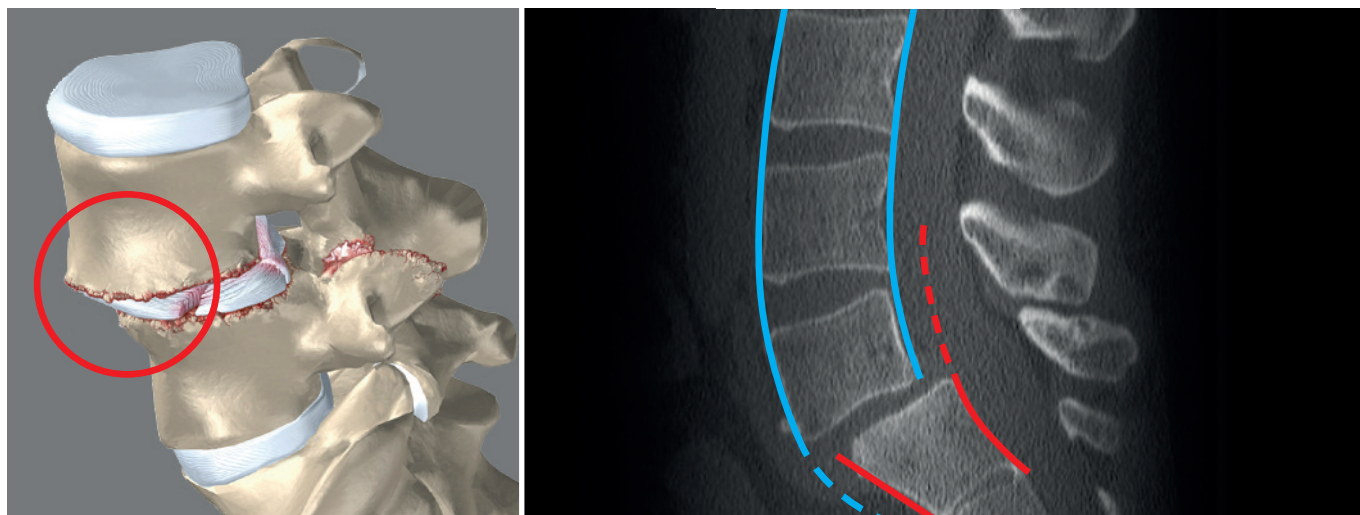
in grade **2** it is less than 50%;

in grade **3** it is less than 75%;

in grade **4**, the entity of the forward displacement can exceptionally reach 100%, with the potential displacement of L5 in the pelvis (Spondyloptosis).

– The intervertebral disc is inevitably involved; as it is no longer protected by the posterior structures, it absorbs functional overloads that exceed its anatomical characteristics, causing it to undergo a degenerative process that leads to flattening and, eventually, to herniation with an exacerbation of the pain symptoms of SL.





The nerve components are often involved with the compression of the dural sac and of the nerve roots of L5 and S1.

The severity of the SL does not often correlate with the intensity of the pain symptoms.

– The symptoms of SL are **1)** mechanical low back pain, which is made worse by movement and improves with rest; **2)** irradiation of pain to the lower limbs.

– Patients often experience a worsening of the pain when changing posture (from sitting to standing).

The following symptoms are less common: discogenic low back pain that gets worse when seated and with the forward flexion of the upper body; facet joint pain that gets worse with the hyperextension of the upper body and when standing; neurogenic claudication (lower extremity asthenia when walking) caused by the spinal canal stenosis that is often present.

– Anteroposterior, laterolateral and oblique projection x-rays, in addition to a dynamic x-ray study in the position of maximum anterior flexion and maximum extension, are essential for the diagnosis of SL.

MRI is used to evaluate the possible compression of the nerve roots and any disc degeneration and/or bulging.

It is not always simple to correlate insta-

bility (such as moderate degenerative SL) with pain symptoms and it is even more arduous to identify **degenerative microinstability** at an early stage.

The real problem, however, is efficacious conservative treatment.

Most patients with SL can be treated conservatively, especially in the presence of the grade 1 and 2 degenerative forms, in which the displacement evolves in approximately **50%** of cases, depending on the case histories considered.

The conservative treatment of SL is essentially physiotherapy-rehabilitation-based: the aim is not only to strengthen the muscles of the upper body in order to stabilize the spine, but also to improve the neuromotor and proprioceptive control of the pelvic girdle muscles, antigravity muscles and respiratory muscles.

– It is, of course, essential to re-educate the patient on how to maintain a good static and dynamic posture.

In the acute phase, when the clinical situation is characterised by persistent low back pain, it is necessary to observe a suitable period of bed rest, associated with the administration of conventional and/or low-dose anti-inflammatories and muscle-relaxants, either individually or in combination.

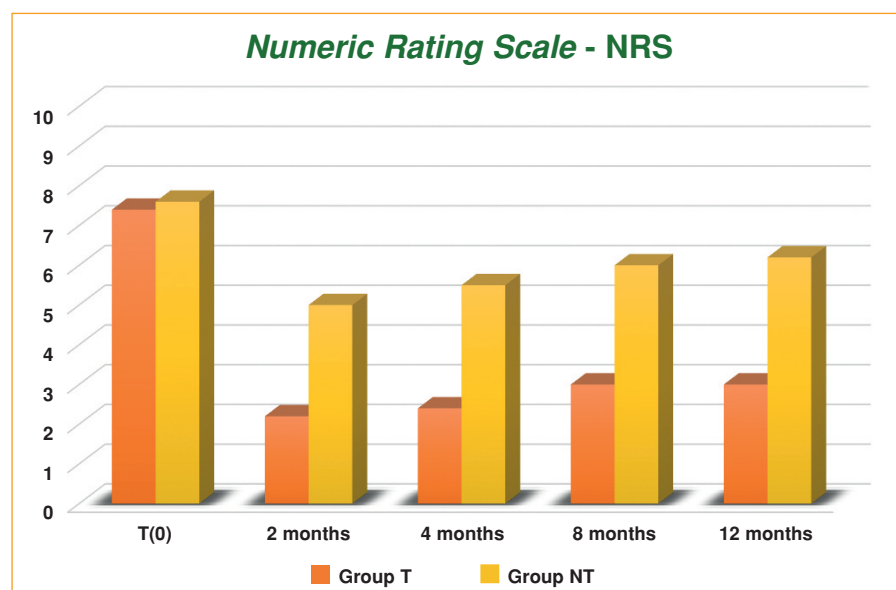
The optimisation of the conservative treatment of low back pain secondary to degenerative SL, taking into account all the anatomical structures involved in this aetiopathogenesis, allows to formulate a number of considerations.

### COLLAGEN MEDICAL DEVICES

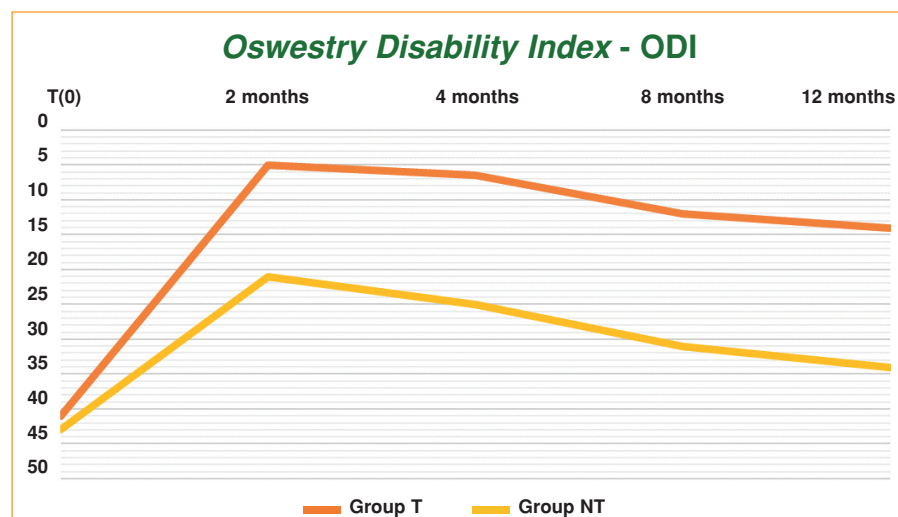
The use of injectable medical devices (**MD**) containing porcine collagen allows a more efficacious and specific *in loco* positioning of the collagen, with a carrier and stabilisation function.

– It makes it possible to replace, strengthen, structure and protect the cartilage, tendons, ligaments and joint capsules, thereby optimising the structure of the collagen fibres and of all the extra- and intra-articular structures in which it is present, thereby providing a mechanical support to the anatomical district in question.

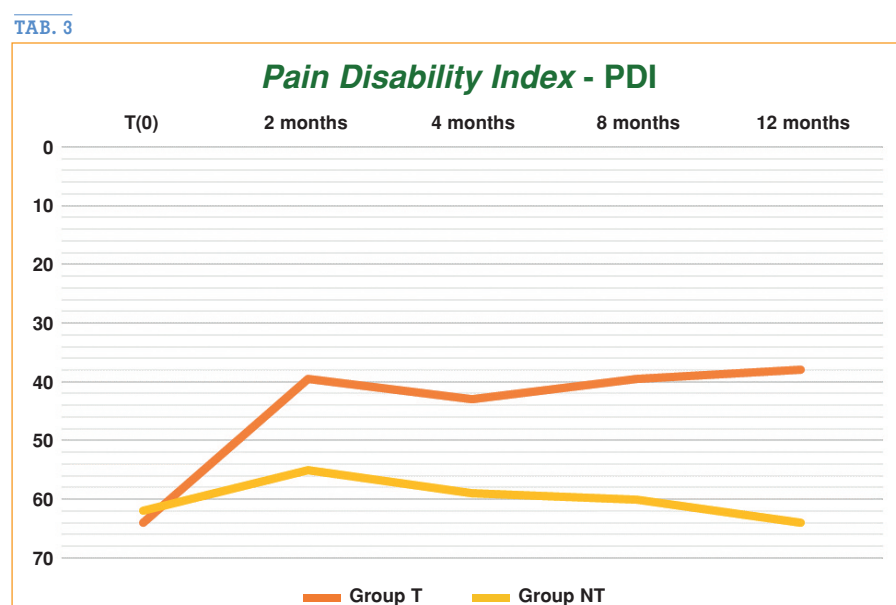
The hypothesis of the study was that a treatment with a specific injectable Collagen MD could re-condition the anatomical structure/s impaired by SL and improve the stability of the lumbosacral spine; that a “combined” treatment would have been able to improve the functional rehabilitation outcomes and/or provide more efficacious pain control in the subacute and chronic phases; and that a combined treatment would also have been able to positively



TAB. 1



TAB. 2



TAB. 3

condition the progression of SL with less frequent exacerbations.

## MATERIALS AND METHODS

In order to explore this hypothesis, **20 patients** with Physical Medicine outpatient clinic appointments for low back pain were recruited and included in the study, from January 2018 to January 2019.

– The patients were randomised to 2 treatment groups [T Group (**Physiokinesis therapy** + ultrasound-guided injections of **MD-Lumbar**) and the NT Group (**Physiokinesis therapy** alone)], stratified by age and gender; the outcomes were assessed at **2, 4, 8 and 12 months**.

### – Inclusion criteria

F and M patients aged between 40 and 75 years; clinical and instrumental diagnosis of **grade 1** and **grade 2 Spondylolisthesis**; NRS (Numeric Rating Scale) > 5, no use of NSAIDs, corticosteroids or opioids.

### – Exclusion criteria

Rheumatoid arthritis, chondrocalcinosis, psoriasis, metabolic bone diseases, gout, active infections, clinical and instrumental diagnosis of grade 3 and grade 4 spondylolisthesis, spondylolysis, polyneuropathy, previous local/epidural corticosteroid injections (> 3 years), use of oral corticosteroid and/or opioid therapy in the past 6 months, use of anticoagulants, pregnancy, mental diseases.

Both the T and the NT Groups were administered the same intra-hospital rehabilitation protocol (diagnostic and therapeutic care programme) based on neuromotor treatment for the proprioceptive reconditioning of the posterior back, lumbosacral girdle and respiratory muscles.

– The protocol also included ergonomic education and occupational therapy.



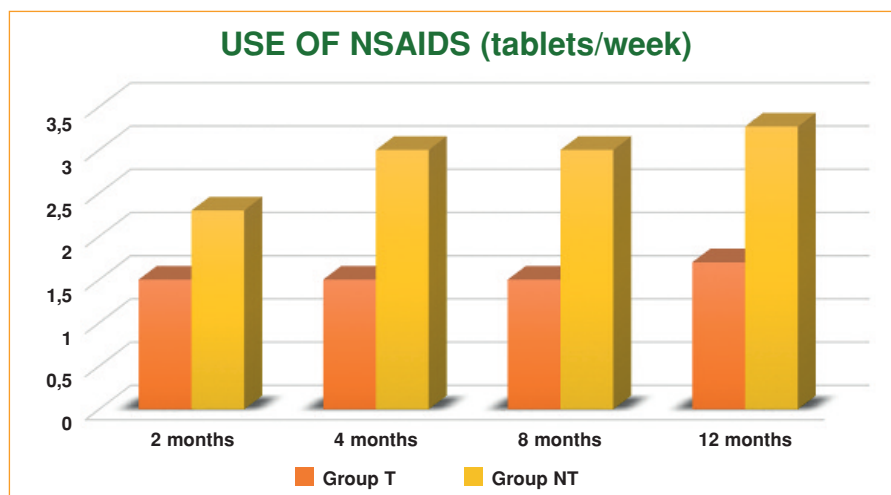
The rehabilitation treatment consisted in:

daily individual motor rehabilitation treatment for a total of ten 45-minute sessions; individual assessment by the occupational therapist at the 5th and 10th session; provision of a brochure illustrating the physiokinesis therapy exercises to be performed by patients at home and ergonomic advices; group treatment (max. 4 patients) one month after the last individual session, on 2 consecutive days, in 30-minute sessions.

• **Group T** (Treatment) also received ultrasound-guided injection therapy (Clarius Ultrasound portable system, Convex probe) according to the following protocol:

5 sessions (1/week for 4 consecutive weeks and 1 after 15 days); **2 vials** of **MD-Lumbar** per treatment.

– Half a vial (1 mL) for each facet joint; 2 joints were treated at each treatment, alternating the upper and lower facet joints; at the 5th session the 2 most impaired joints (as shown by MRI) were treated.



TAB. 4

A number of clinical and functional outcomes were investigated:

- 1) Numeric Rating Scale (**NRS**)
- 2) Oswestry Disability Index (**ODI**)
- 3) Pain Disability Index (**PDI**)
- 4) use of NSAIDs during the follow-up period (TABLES 1, 2, 3 and 4).

## CONCLUSIONS

The data obtained (TAB. 5) allow to conclude that in the treatment of grade 1 and

grade 2 Spondylolisthesis combined treatment with physiokinesis therapy + injection of MD-Lumbar makes it possible to obtain a far **better** and **longer-lasting improvement**, in terms of

- 1) pain
- 2) motor function
- 3) impairment caused by spinal instability
- 4) reduced use of NSAIDs.

Furthermore, the combined treatment proposed herein, for the first time in the

OUTCOMES	T (0)		2 months		4 months		8 months		12 months	
GROUPS	T	NT	T	NT	T	NT	T	NT	T	NT
<b>NRS</b> <i>Numeric Rating Scale</i>	6,9	7,1	1,7	4,5	1,9	5,0	2,5	5,5	2,5	5,7
<b>ODI</b> <i>Oswestry Disability Index</i>	41,0	42,0	5,0	21,0	7,0	25,0	12,0	31,0	14,0	34,0
<b>PDI</b> <i>Pain Disability Index</i>	64,0	62,0	40,0	56,0	42,0	58,0	40,0	60,0	38,0	64,0
<b>NSAIDs</b> <i>tablets/week</i>			1,3	2,0	1,3	2,7	1,3	2,7	1,4	3,0

TAB. 5

From the data obtained, it emerges that:

- **NRS.** Group T (Physiokinesis therapy + ultrasound-guided injection therapy of MD-Lumbar) passes from 6.9 (T0) to 2.5 after 12 months (-63.8%). Group NT (Physiokinesis therapy alone) passes from 7.1 (T0) to 5.7 after 12 months (-19.7%).
- **ODI.** Group T passes from 41.0 (T0) to 14.0 after 12 months (-65.9%). Group NT passes from 42.0 (T0) to 34.0 after 12 months (-19.1%).
- **PDI.** Group T passes from 64.0 (T0) to 38.0 after 12 months (-40.6%). Group NT passes from 62.0 (T0) to 64.0 after 12 months (±0%).
- **NSAIDs (tablets/week).** Group T passes from 1.3 at 2 months to 1.4 at 12 months (±0%). Group NT passes from 2.0 at 2 months to 3.0 at 12 months (+50%).

treatment of Spondylolisthesis, would appear to allow a better control over disease progression and a reduction in exacerbations over time (pro-inflammatory cytokine network control).

- **MD-Lumbar** improves the stability of the lumbosacral spine and organically reconditions the impaired anatomical structures (joint capsules, yellow ligament, antigravity muscles and connective deep fascia), thereby making a considerable contribution to the promotion of neuromotor and proprioceptive capacity.

Over the next few months, we hope to be able to confirm the results obtained by expanding the study sample and, in particular, to identify the optimum timing for further injection therapy with MD-Lumbar as part of an individual maintenance rehabilitation programme. ■

## Literature

1. Alfieri A., Gazzeri R. – The current management of lumbar spondylolisthesis. *J. Neurosurg Sci.* 57: 103; **2013**.
2. Arvind G. *et al.* – Should we label all synovial cysts as unstable? *Global Spine Journal.* 7: 629; **2017**.
3. Evans N. *et al.* – Management of symptomatic degenerative low-grade lumbar spondylolisthesis. *EFORT Open Rev.* 3: 620; **2018**.
4. Hildebrandt M. *et al.* – Correlation between lumbar dysfunction and fat infiltration in lumbar multifidus muscles in patients with low back pain. *BMC musculoskeletal Disorders.* 18: 12; **2017**.
5. Huang K.Y. *et al.* – The roles of IL 19 and IL 20 in the inflammation of degenerative lumbar spondylolisthesis. *Journal of Inflammation.* 15: 19; **2018**.
6. Jae-Sung K. *et al.* – Characterization of degenerative human facet joints and facet joint capsular tissues. *Osteoarthritis Cartilage* 23: 2242; **2015**.
7. Massullo C. – I Guna Collagen Medical Device nella ripresa funzionale dopo traumi sportivi. *La Med. Biol.*, **2017**/2; 45-50.
8. Milani L. – Un nuovo e raffinato trattamento iniettivo delle patologie algiche dell'Apparato locomotore. Le proprietà *bio-scaffold* del collagene e suo utilizzo clinico. *La Med. Biol.*, **2010**/3; 3-15.
9. Milani L. – I Guna *Collagen Medical Devices* 10 anni dopo. Analisi ragionata di 2 recenti importanti ricerche e *update* della letteratura. *La Med. Biol.*, **2019**/2; 3-18.
10. Pavelka K. *et al.* – MD-Lumbar. MD-Muscle e MD-Neural nella terapia locale del dolore lombare. *La Med. Biol.*, **2012**/4; 13-17.

11. Pavelka K. *et al.* – Chronic Low Back Pain: Current Pharmacotherapeutic Therapies and a New Biological Approach. *Current Medical Chemistry*, **2018** May 13, 25: 1-8.
12. Russo G. – Portale Medicinafisica.it; **2019**.
13. Shahidi B. *et al.* – Lumbar multifidus muscle degenerates in individuals with chronic degenerative lumbar spine pathology. *J. Orthop Res.* 35: 2700; **2017**.
14. Tian G., Qi L. – Correlation between facet tropism and lumbar degenerative disease: a retrospective analysis. *BMC Musculoskeletal Disorders*, 18: 483; **2017**.
15. Wagner S.C. *et al.* – Severe lumbar disability is associated with decreased psoas cross-sectional area in degenerative spondylolisthesis. *Global Spine Journal*, 8: 716; **2018**.
16. Zocco R. *et al.* – Effectiveness of integrated medicine in the control of pain in vertebral disorders: observational study. *Physiological Regulating Medicine*, **2012**; 41.

**Fig. p. 40**

<https://urbanministries.com/wp-content/uploads/2019/01/iStock-927091262-Pain.jpg>

**Fig. p. 41**

**Left:**

[https://eorthopod.com/images/ContentImages/spine/spine\\_lumbar/lumbar\\_spondylolistheis/lumbar\\_spondylolisthesis\\_cause02.jpg](https://eorthopod.com/images/ContentImages/spine/spine_lumbar/lumbar_spondylolistheis/lumbar_spondylolisthesis_cause02.jpg)

**Right:**

[https://www.brainspinesurgery.com/uploads/img/\\_800xAUTO\\_crop\\_center-center\\_60/Spondylolisthesis-Spine-Condition-and-Symptoms-Xray.png](https://www.brainspinesurgery.com/uploads/img/_800xAUTO_crop_center-center_60/Spondylolisthesis-Spine-Condition-and-Symptoms-Xray.png)

**Paper presented at the  
2<sup>nd</sup> INTERNATIONAL CONGRESS**

**"COLLAGEN IN THE PATHOLOGIES OF  
THE MUSCULO-SKELETAL APPARATUS  
- Painful diseases of Joint & Muscle System.  
Important contribution of Collagen Medical  
Devices"**

**Milan, 16<sup>th</sup> November 2019**

**author**

**Edoardo Milano, MD**

– Director of the Department of Physical Medicine and Rehabilitation  
San Camillo Hospital

Turin, Italy