

S. Ben-Yakir



EQUINE SACROILIAC LUXATION -AN INNOVATIVE THERAPEUTIC APPROACH

The aim of this study is providing a complementary veterinary medicine tool to be used for **equine sacroiliac luxation**.

The equine sacroiliac articulation is represented in [Figure 1](#).



Vertebral disorders and injuries of the sacroiliac joint have been identified as substantial causes of chronic poor performance in horses. Soft-tissue injuries of the back and pelvis include **the luxation of the sacroiliac joint**, among other conditions (1-8).

The conventional treatment for luxation usually consists in complete rest and anti-inflammatory drugs administered in the acute stage, followed (especially in chronic conditions) by local injections of "irritants" in order to produce scar tissue (Prolotherapy).

-Using Prolotherapy, a cicatrized wound easily undergoes relapses, and prognosis is cautious.

Since all cases included are high-performance horses, we should keep in mind that a horse treated with a conventional therapy can take part in new sports events, but it is unlikely it will be able to perform as previously.

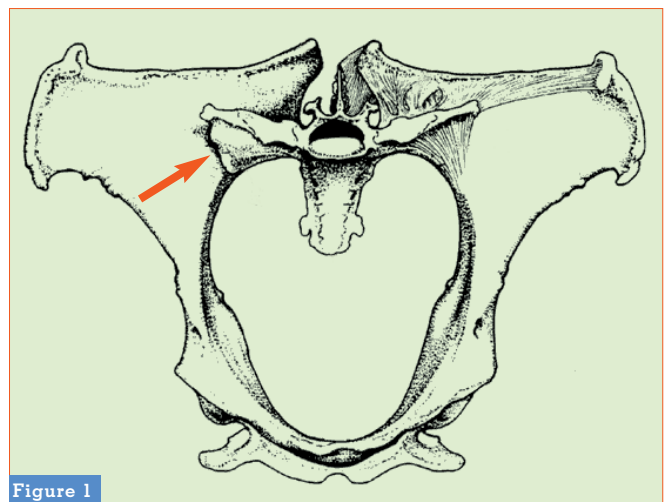


Figure 1



Figure 2

The concept this clinical trial was based on was to establish an alternative to the conventional protocol – one that would give a better prognosis, especially in high performance horses.

– In the last decade, **65 horses** suffering from chronic sacroiliac luxation have been treated, seen by our mobile clinic after initial diagnosis and primary symptomatic relief by local veterinarians.

The horses came from different areas of Israel; enrollment to this trial was promoted through lectures to veterinarians and horse farm owners from all over the state.

- 56 horses were included in our therapy sessions; the owners of the remaining 9 horses chose the conventional protocol, thus forming the Control Group.

All 56 horses were competition horses: 38 were Thoroughbred race horses (flat racing), 9 were Quarter Horses competing in reining, and 9 were Arabian horses competing in flat racing.

The horses' age ranged between 2 and 5 years, the sex ratio was 50:50, and all were sexually intact.

– In 49 horses the “high side” was on the right (Figure. 2). Horses were seen by the author in a period included between 2 and 6 months after diagnosis and initial treatment; such visit

was due to poor performance during training or to the owners' dissatisfaction with current treatments and/or prognosis.

All 56 horses received the same treatment protocol:

1) Injection of **GUNA-LUMBAR** and **GUNA-HIP** in three acupuncture points (Table 1) every 14 days, 3 treatments (Day 0, Day 14, and Day 28), using a method known as “biopuncture.”

2) Stretching the hind legs: the rear leg on the “high side” was stretched back and held for 30 seconds; one minute later the rear leg on the “low side” was stretched forward and held for 30 seconds. The legs were lifted as far as the horse would allow. The stretching was done three times per day for 28 days (until the last injection).

3) Walking: during the 28 days of treatment, all horses were only allowed to be walked by a handler within farm limits. – No other exercise was permitted.

After 28 days of treatment, each horse was evaluated by our mobile clinic team and its referring veterinarian, trainer, and jockey for **pain, stiffness, lameness, presence of malformation, and willingness and ability to perform.**

52 horses resumed their original training sessions and went back to racing, and for 4 horses no improvement was seen and the owners sent them for breeding only.

► In our surveillance up to now, we did not see any repetition of the original problem. It is worth noting that one of the Thoroughbreds (“Yagud,” also known as “Dino”) won **17** out of **22** races after coming back to racing, and was given the title of “Horse of the Year” by the Israeli racing horse committee.

Another horse (Quarter Horse) won the Israeli championship for reining. The owners of the control group (9 horses) saw no improvement in their horses and sold their horses a year later, since they were found to be unfit to high level performances.

• It seems that the combination therapy consisting of GUNA products injected into specific acupuncture/anatomical

Acupoint Used in Treatment	Anatomical Location	Technical Information
<i>Baihui</i>	In the lumbosacral space	Spinal needle, 21 G, 90 mm, perpendicular insertion, 6 cc GUNA-LUMBAR
BL40 = Wei-zhong, Both legs	Midpoint of the transverse crease of the popliteal fossa (Kneepit)	25 G, 16 mm needle, perpendicular insertion, 2 cc GUNA-HIP

Table 1
Acupuncture Points chosen for the therapy.

points along with physical manipulation provides important benefits to performing horses with chronic sacroiliac luxation.

– The prognosis is favorable (90% success rate) for coming back to high performance and reaching the maximum potential of the horse. ■

References

1. Adams O.R. – Lameness in Horses, 3rd ed. Lea & Febiger. **1979**; 292-296.
2. Haussler K.K. *et Al.* – Pathological changes in the lumbosacral vertebrae and pelvis. *In* Thoroughbred racehorses. *AJVR*, 60(2); **1999**, 143-153.
3. Jeffcott L.B. – Disorders of the thoracolumbar spine of the horse—a survey of 443 cases. *Equine Vet J*, 12:197-210; **1980**.
4. Jeffcott L.B. – Pelvic Lameness in the Horse. *Equine Pract*, 4:21-47; **1982**.
5. May S.A., Harrison L.J. – Radiography of the hip and pelvis. *Equine Vet Educ*, 6:152- 158; **1994**.
6. Rooney J.R., Delaney F.M. *and* Mayo J.A. – Sacroiliac luxation in the horse. *Equine Vet J*, 1:287-289; **1969**.
7. Rooney J.R. – Sacroiliac luxation. *Mod Vet Prac*, 60:45-46; **1979**.
8. Wagner P.C. – Diseases of the spine, pp 1145-1158. *In* *Equine Medicine and Surgery*, 3rd ed, Mansmann RA and McAllister ES, Eds, American Veterinary Publications, Santa Barbara, CA. **1982**.

author

Dr. Sagiv Ben-Yakir

– Doctor in Veterinary Medicine
 – Member of Royal College of Veterinary Surgeons (MRCVS)
 P.O. Box 3337
 Ramot - Hashavim, Israel