



THERAPEUTICS

L. Milani

SUMMARY

Connective tissue and collagen in particular – a real protein-tissue – progressively degrade and reveal to be inadequate to perform the functions they are to accomplish in each organism. This is due to aging, sedentarity, intense physical activity or inadequate sports activity, postural alteration, alimentary disequilibrium, and PNEI-axis alteration. Specific injectable Medical Devices (MD) (both distrectual and tissular) represent a new and refined tool in prevention and therapy to treat the ageing of articular structures, as well as periarticular ones and those concerning mesodermic supporting tissues. These MDs replace the lack of collagen, which is always recurrent in the inflammatory and/or degenerative diseases of the locomotor Apparatus and other anatomical structures of mesodermic origin; they are natural, free from negative side effects (excellent safety); they can be associated with homotoxicological therapies as well as allopathic ones that are being applied or that will be scheduled; moreover, they can be associated with physical therapies. Non-invasiveness of injections using Guna MDs – which are the first to highlight quality therapeutic results in 7 controlled clinical trials [Registration Dossier c/o Istituto Superiore di Sanità (Italian Superior Health Institute)] – together with other characteristics such as effectiveness, tolerability, absence of allergic reactions and their natural origin make them a valuable tool in standard procedures (both in treatments by specialists or general practitioners) and in processes aimed at improving the patients' quality of life, which could otherwise worsen or become further chronic.

KEY WORDS

COLLAGEN, MEDICAL DEVICE, ANCILLARY SUBSTANCE, GUNA MEDICAL DEVICE, PAIN, OSTEO-ARTHRO-MYO-FASCIAL PATHOLOGIES

A NEW AND REFINED INJECTABLE TREATMENT FOR MUSCULOSKELETAL DISORDERS – BIOSCAFFOLD PROPERTIES OF COLLAGEN AND ITS CLINICAL USE

COLLAGEN – COMPOSITION AND ACTION

Collagen is the most abundant protein (structural protein – tissue; molecular weight 300KDa) in mammals' organism – accounting for about 5-6% of an adult's body weight (Van der Rest *et Al.*, 1991); one third (Trentham *et Al.*, 1977) or one fourth (Lynsenmeyer, 1991) of the whole protein mass of higher animals is composed of collagen: bones and tendons, joint capsules and muscles, ligaments and fascia, teeth and serous membranes, the skin and the extracellular matrix (ECM).

– According to some hypotheses, the ancestral gene that synthesizes collagen has evolved to its present form due to further mutations starting from one single unit composed of only 54 base pairs of DNA.

At present the alpha 2 collagen gene is composed of about 38.000 base pairs.

– The basic difference between **functional proteins**, which are involved in biochemical, enzymatic, immune, membrane and/or transmembrane re-

ceptor processes, and **structural proteins**, which play an important role in building the scaffold of higher organisms (connective tissue in a wider sense and more specifically – fibrous tissue) is not considered so important for collagen.

For example, collagen VI plays an essential role in the processes of cell adhesion, replication and survival through its interaction (*cross-talk*) with integrins and/or other transmembrane receptors (Pfaff *et Al.*, 1993; Jan *et Al.*, 2004), showing both roles: the genetic absence of Collagen VI causes severe morpho-functional alterations of muscle fibres and apoptosis by acting directly on the mitochondrion (Rizzuto, 2003) due to a failure to regulate cell permeability (last author mentioned).

– **Collagen "health"** is ultimately the **individual's health**: man's peak of collagen biosynthesis occurs between 45 and 60 years of age (Heine, 2009): after that age there is a rapid decrease of collagen that is also accompanied by a rapid decrease of elastin and proteoglycans (Milani, 2004 a) (FIG. 1).

An insufficient renewal of the ECM brings about a sluggish function of the

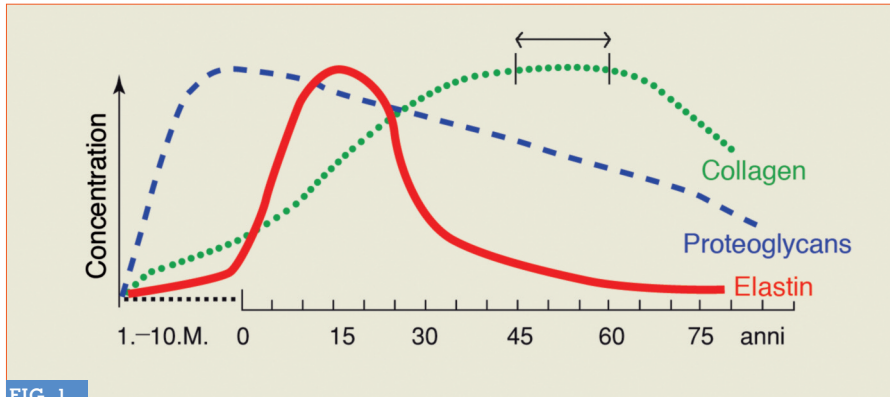


FIG. 1

Life curve of the most important macromolecules of the extracellular matrix (in Heine, 2009).

Transit System (Pischinger, 1983). Faulty routing of waste will cause the accumulation of toxins usually directed by the cells in the microvessels of the lymphatic system; this impacts oxygenation of tissues, nutrient assimilation and hydration. Fragility and sclerosis are silent symptoms preceding degeneration and possible tissue dedifferentiation (disease evolution according to Reckeweg).

The base unit of collagen is **tropocollagen** (FIG. 2), a glycoprotein composed of three left-handed helices of polypeptide units carrying glucose and galactose molecules that are attached **only** to the molecule of the amino acid hydroxylysine (Hyl), one of the only four amino acids that form tropocollagen with Glycine (Gly), Proline (Pro) and 4-Hydroxyproline (Hyp).

Tropocollagen has some interesting structural “anomalies” compared to other proteins:

– In the molecule:

- 1) Every triplet of amino acids always starts with Glycine (Gly-A-B);
- 2) The amino acid sequence is often represented by the triplet Gly-Pro-Hyp;
- 3) These triplets cannot usually be found in other proteins and have to be considered unique and special;
- 4) Proline determines the twisting, the “change of direction” along the axis of the protein strand; that’s why it is absolutely absent in globular proteins;

- 5) Many residues of Hyp have two sugar residues.

Therefore, collagen is a glycoprotein (great amount of protein – small amount of sugar) and not a proteoglycan (PG) (great amount of sugar – small amount of protein);

The collagen imbalance of sugar/protein ratio balances that of PGs.

- 6) Axial periodicity (text, see after: FIG. 6), a true metamerism that is visible only with the electron microscope.

These “anomalies” guarantee a perfect strength and function of the molecule: when the three polypeptide units are intertwined in a tight triple helix, stabilized between hydroxylated amino acids (*crosslinks*) by weak H⁺ bonds, they give basic and special characteristics to collagen 2: structural **strength** and organoleptic **rigidity**. The spatial configuration of tropocollagen is a cylindrical braid composed of three rods wrapped in an helix. This gives the molecule great **resistance** and **flexibility**: to break a 1 mm diameter collagen fiber an 11 kg weight must be applied to each end.

The hydrogen bond is a weak, non-covalent bond: it is the number of atoms that gives it its strength, as it occurs with fibroin, the structural protein of silk.

The hydroxylation of Pro and Hyp and the hydroxylation of Lys and Hyl occur thanks to the cofactor ascorbic acid (Vitamin C) and to the substrate

acidum α -ketoglutaricum, one of the three-carboxylic acids of Krebs’ Cycle. A deficit of one of these metabolic boosters will cause severe alterations of the connective tissue which can manifest as scurvy and cancer cachexia.

A failed hydroxylation to Hyp and Hyl leads to the formation of a collagen fibril that is structurally and functionally impaired.

According to the different types of collagen involved some severe genetic cases of *Osteogenesis imperfecta*, Bethlem myopathy, Ulrich’s sclero-tonic muscular dystrophy, mitochondrial myopathy may occur, just to mention a few that illustrate the truth behind Garrod’s “old” theory (1902) – “one gene, one enzyme” which still applies today.

► The diseases due to an acquired collagen deficiency are also thought to have their pathogenesis in a faulty synthesis and use of collagen (TAB. 1).

– I would like to remind that Lys, precursor of tropocollagen 5-Hyl is an **essential amino acid** that must be sourced from food and/or from supplementation.

– Collagen biosynthesis is carried out by different cell lines (fibroblasts in the loose and fibrous fibrillar connective tissue, osteoblasts in bones, chondroblasts in cartilage, etc.)

After the amino acids interlock, the **globular procollagen** is produced at an intracellular level and is pushed outwards through the Golgi apparatus (Olsen, 1983) (FIG. 3). Here, thanks to the shortening of the 2 telomeres (one N-terminal, the other C-terminal), the procollagen turns into **procollagen**; as soon as procollagen is being formed, this produces a negative feedback on the collagenous-genetic cell, by inhibiting a further synthesis.

– The procollagen microfibrils are therefore polymerized outside the collagenous-genetic cell.

The single units of procollagen are staggered thanks to Lysyl-oxidase, linearly and in parallel array to gradually form one microfibril, one subfibril, and

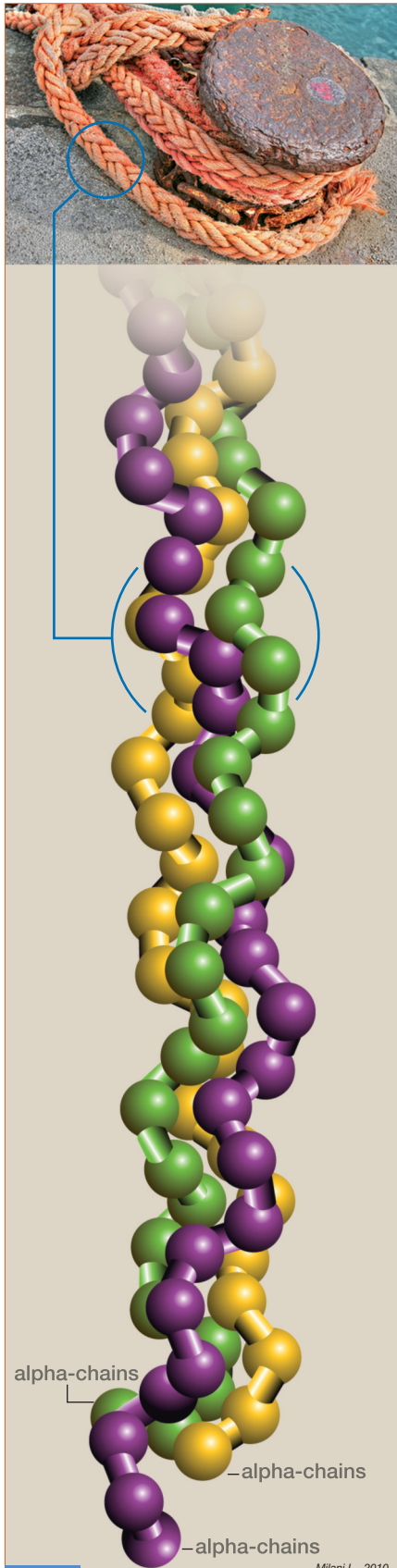


FIG. 2 Milani L., 2010

The triple helix (three alpha-chains) of tropo-collagen, the basic unit of mature collagen.
 - The molecule is stabilized by the presence in the alpha chains of hydroxylated amino acids whose H⁺ bonds give it strength and rigidity.

SOME OF THE MOST IMPORTANT AND FREQUENT ACQUIRED COLLAGENOPATHIES
- PRIMARY CHRONIC POLYARTHRITIS (RHEUMATOID ARTHRITIS)
- STILL'S SYNDROME
- FELTY'S SYNDROME
- ANCYLOSING SPONDYLITIS (STRÜMPPELL-BECHTEREW-MARIE DISEASE)
- REITER'S SYNDROME
- SCLERODERMIA
- SLE
- DERMATOMYOSITIS
- POLYMYOSITIS
- KUSSMAUL PANARTHRTITIS
- HORTON'S TEMPORAL ARTHRITIS
- MOSKOWITZ PURPURA
- GOODPASTURE'S SYNDROME
- MOYAMOYA DISEASE
- TAKAYASU'S SYNDROME
- SHARP'S SYNDROME (mixed connective tissue disease)

Milani L., 2010

TAB. 1

one collagen fibril. (FIG. 4).
 Several collagen fibrils constitute a collagen fibre.

- This process is thought to occur, at least partly, via an autocatalytic route (Prockop, 2004; Cisneros et Al., 2006).
 In some rare moments biology by-passes the rigid genetic determinism and the most flexible epigenetic possibilism and shows great adaptability supported by autocatalysis with more flexibility and adaptability (Lima de Faria, 2003).

This undermines deeply the Darwinian and post-Darwinian pure evolutionary theory (Milani, 2009).

- The fibrils are characterized by a periodicity: they show small structural units along their own course which repeat every 670 Amstrong [FIGG. 5 (1, 2), 6].
 - The reason for this periodicity (a true structural form), which has been sought for a long time, is simple: as both fibrils and the collagen fibres are

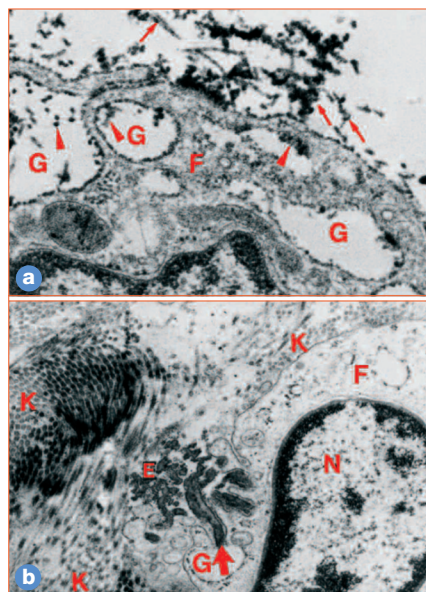


FIG. 3

Synthesis and extracellular cross link of collagen and elastin;
F = fibroblast; G = Golgi (vesicles);
K = Collagen, E = Elastin, N = Cell nucleus.
a After the release and the "cutting" of telopeptides, tropocollagen molecules are formed (→) these bind to collagen fibrils (2.400X);
b Release of elastin precursors (tropo-elastin) from a Golgi vesicle and neo-synthesis of elastin (→) (2.400X).

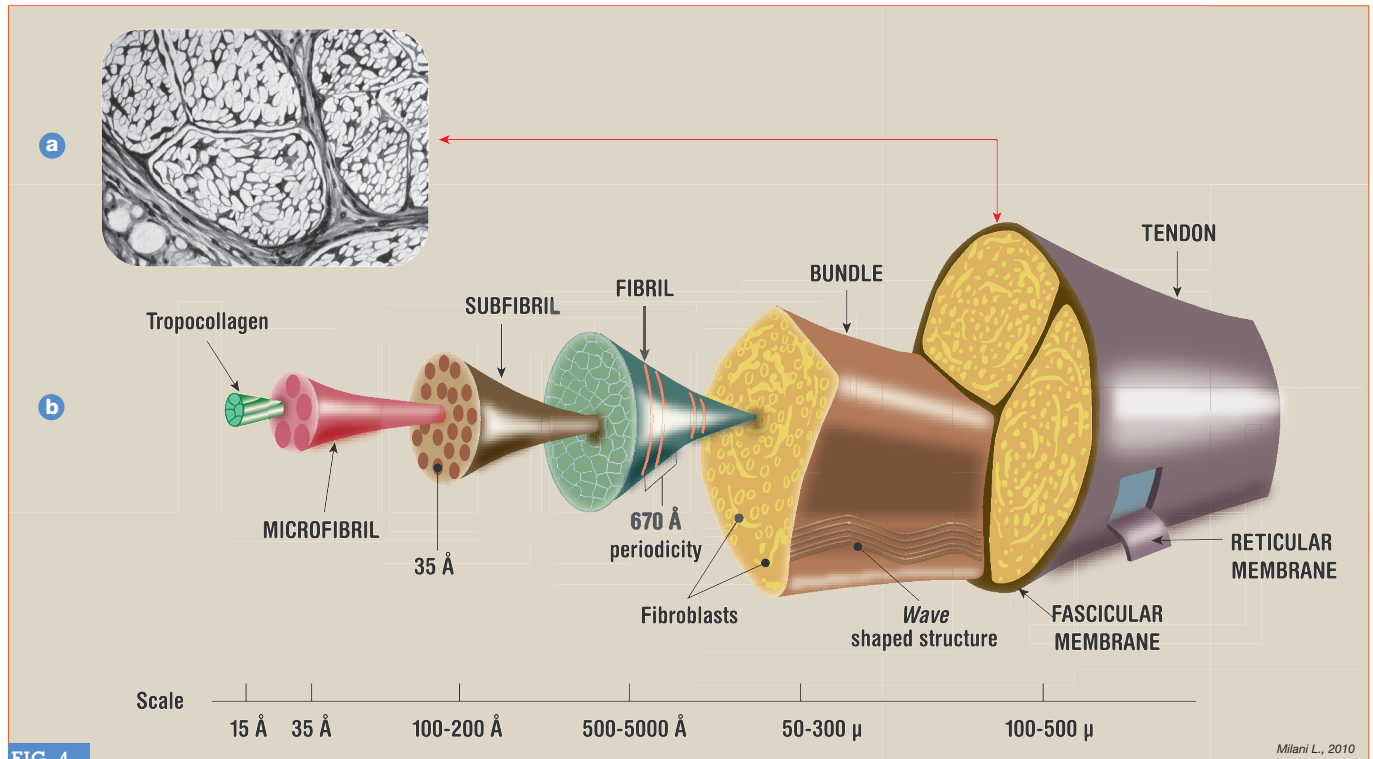


FIG. 4

Milani L., 2010

a Tendon in cross-section [350X magnification (Chèvremont)]. The collagen fibers are grouped in segmented bundles of different levels.
b Hierarchical structure of the tendon acc. to Kastelic et Al., 1978 (reconstructed, updated by the author).

much longer than the maximum diameter of the cells that synthesize them, the basic collagen molecules must be small enough to be secreted and polymerized afterwards.

If a tropocollagen fibre is 2,800 Amstrong long, how can we justify a 670 Amstrong axial periodicity? This is possible **only if** the underlying fibrils are out of phase of one quarter compared to the overlapping fibrils (Hodge and Petruska model, 1964) and **if** these do not relate by the ends but rather line up in a way that there is a half length period between their own extremities (1 dark segment + 1 light segment = 1 period).

Each molecule of tropocollagen is composed of 5 light segments spaced out by 4 dark segments. Thanks to the use of Conventional Amplitude Modulation (AC Imaging) structural models have been recently proposed, different from the traditional model that is recognized by the scientific community (Bozel et Al., 2007), even if a new convincing molecular scheme has not yet been defined (Jiang et Al., 2009).

► Such arrangement of the fibrils in the formation of collagen fibres guarantees a great strength in terms of:

- RESISTANCE
- NON-EXTENSIBILITY
- NON-COMPRESSIBILITY, but also
- PLASTICITY
- FLEXIBILITY
- LOAD RESISTANCE
- TORSION RESISTANCE

These characteristics make collagen an extremely versatile "structure" that Nature has been selecting during hundreds of millions of years and upheld as the best means to fulfil its many functions.

Besides these characteristics, collagen is the prerequisite for the activation of the repair process of all the body tissues.

- Before concluding this section, I would like to point out a further characteristic of collagen that is little known, but extraordinary: **piezoelectricity**, an electric charge generated by

pressure, traction, torsion (Athenstedt, 1974).

Thanks to its helical structure, collagen, an out-and-out electric dipole, can **oscillate** thus piloting the growth and the orientation of the neo-fibrils.

From this point of view, a special electromagnetic activity is ascribed to the large trabeculations of the connective tissue that are located between the big muscular bundles and their tendons of origin and insertion.

Heine (2009), resuming the work by Bergsmann and Bergsmann (1997), suggests that the large connective *trabeculae* clearly correspond to the Chinese Acupuncture Meridians.

- In any case, they can be found more frequently between antagonistic muscle groups (Milani, 2004 b), which raises the real possibility to intervene therapeutically with injections of collagen in these points/areas in cases of osteo-arthritis and local myo-fascial interstitial pathologies.

THE ARTICULAR STABILIZATION SYSTEMS – THE COLLAGEN REIGNS

The restraint and stabilization function of each joint must ensure two principles in apparent opposition: **stability** and **locomotion**.

Later we are going to explain how the anatomical alterations that cause changes in one or both of these functions, cause dysfunctions and pathologies of the skeletal muscle, with resulting motor deficit.

The stabilization systems are represented by stabilizing structures that cooperate at different levels for an optimal articular functionality.

1 – EXTRA - ARTICULAR COMPARTMENT

(FIG. 7)

– LIGAMENTS

Intra-articular (only big joints) and extra-articular elements consisting of a parallel system of collagen bundles. By examining the conditions under which the ligaments are put under tension-traction, it is easy to determine the reason why they can be blocked or prevented from movement.

– INTRA ARTICULAR CAPSULE

The covering element for protection and reinforcement of the joint, is fixed on the two elements of the adjacent bones. In smaller joints, the line of intersection is located along the edge of the articular cartilage. The capsule consists of interwoven heavily and closely staggered bundles of collagen, zones of less dense fibrillar tissue and adipose lobules.

The collagen bundles that form the joint capsule are never arranged longitudinally between the two articular heads, but rather obliqually following the intertwined trajectories thus forming a strong and rigid capsule.

– TENDONS

The long tendons connecting one section with the other of the locomotor

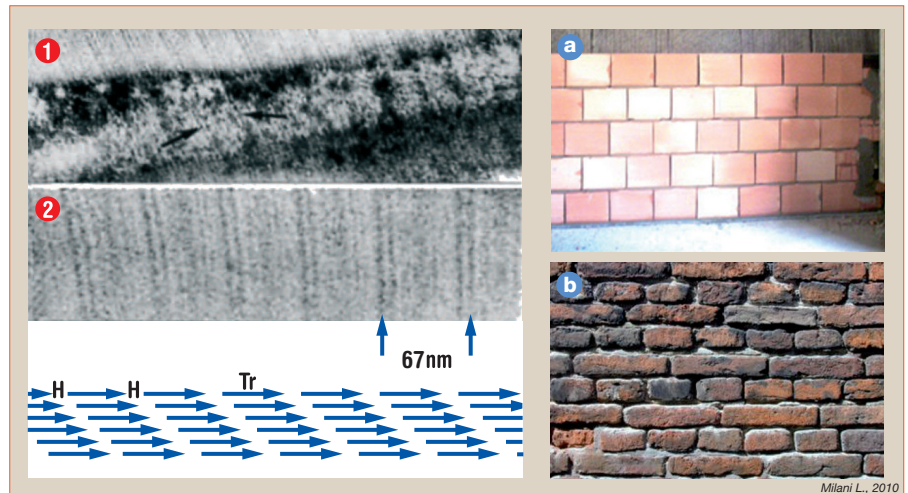


FIG. 5

1: Sugars linked to collagen (ruthenium red colour). **Correlation of sugar** (black precipitations) **to the periodicity of collagen fibrils** (ME 112.000X);

2: Section of a collagen fibril (ME 240.000X). **A cycle of 67 nm** (670 Å) **is formed on the basis of collagen molecules each time slipped of one-quarter of their length.**

a This placement of bricks responds well to the pressure from above, not to the tangential one.

b This placement of bricks responds well to the pressure from above, and to the tangential forces: this provision shows a displacement of many bricks compared to the overlying ones of ca. one quarter of the length of the single element (author, 2010).

system are provided with restraint elements that keep the two sections in contact with the bone axis during the joint movement.

The tendons are strengthened and protected by mucous sheaths, in some cases along the whole stretch of sliding. Between tendon and sheath there is a lubricant liquid, similar to the synovial fluid, which facilitates the tendon sliding.

– MUSCLES

Also the muscles are involved in the articular resistance through their sur-

face coating bundles (coating aponeurosis), deep fascia, connective tissue which sometimes acts as an individualized *lamina*, and intermuscular *septa*. If the restraining function of the muscles is insufficient, only the capsule and ligaments ensure this function: their resistance is below the threshold of effort, and the joint is exposed to not sustainable risks.

– Many cases of mild to medium severity of hip dysplasia can be controlled by inducing hypertrophy of the surrounding muscles by means of specific physical exercises and nutritional sup-




FIG. 6

Ultrastructure of the collagen. Native collagen fibril type I (AFM images).

– **The most recent ultrastructural measurements show a period of 67 nm** (670Å) **and not of 64 nm, as previously reported by various Authors and frequently even by scientific literature and in medical textbooks.**

– **Collagen shows a clear and defined "metameric" structure with a simple or elementary recurrent base scaffold.**

plementation with MAP-Son Formula (*personal observations*).

Even after many years the situation of X-ray shows only minimal endoarticular alterations that are compatible with normal mobility and quality of life.

2 – INTRA-ARTICULAR COMPARTMENT

– LIGAMENTS

Intra-articular ligaments of the big joints (FIG. 8).

– ARTICULAR CARTILAGE

The great Italian anatomist R. Amprino (Anatomical Institute, University of Turin), had the merit to carry out the early studies on the mechanical function of the collagen fibrils of the hyaline cartilage in man (Amprino, 1938). The collagen fibrils are arranged in vertical bundles in the fundamental substance of the deep layer while they are

arranged tangentially on the surface layer.

Overall, the fibrillar arches form a structure similar to a Romanesque arch (FIG. 9); this is an optimal architectural solution for well withstanding the pressure from above and tangential forces exerted during the joint movement.

All extra-and intra-articular structures consist basically of collagen.

– The (rare) genetic-metabolic alterations, mechanical alterations (recurring microtrauma, trauma), abnormal posture, age (chrono-aging) acquired collagenopathies, chronic inflammatory diseases and cancers **damage the integrity of collagen fibers** and - consequently - of the support system as well as the mechanical function of the whole organism.

Some studies carried out by Ozaki et

Al., (1988) and Riley et Al., (1994) show - in autopsy reports – flagrant changes in the composition of collagen in rotator cuff tendinitis and how the body triggers the collagen neosynthesis in an attempt to remodel the micro-damage and repair the tendons involved, also in elderly.

The electron microscope photographs shown in Provenzano et Al., (2001) on the ultrastructure of the repair process of medial collateral ligament injuries of the knee, are very exhaustive (FIG. 10).

– Gronemann et Al., (2004) show that patients affected with fibromyalgia in non-tender (non-trigger) points have lower levels of Hyp compared with healthy controls and - in general - a lower total concentration of amino acids in collagen.

The amount of total protein and myosin are within normal range.

Electron microscopy shows atrophic muscle fibrils **only** in cases of fibromyalgia.

The above mentioned Authors conclude that fibromyalgic patients have significantly reduced collagen amount in the muscles and this could lower the threshold for muscle microtrauma (FIG. 11).

The results of these studies confirm those of Yunus et Al., (1986), Savolainen et Al (1987), and Mackey et Al., (2002). – Xu and Shen (2007) show that the oral administration of collagen reduces the degeneration of articular cartilage and the levels of intracartilage MMP-13, MMP-9, and cathepsin K.

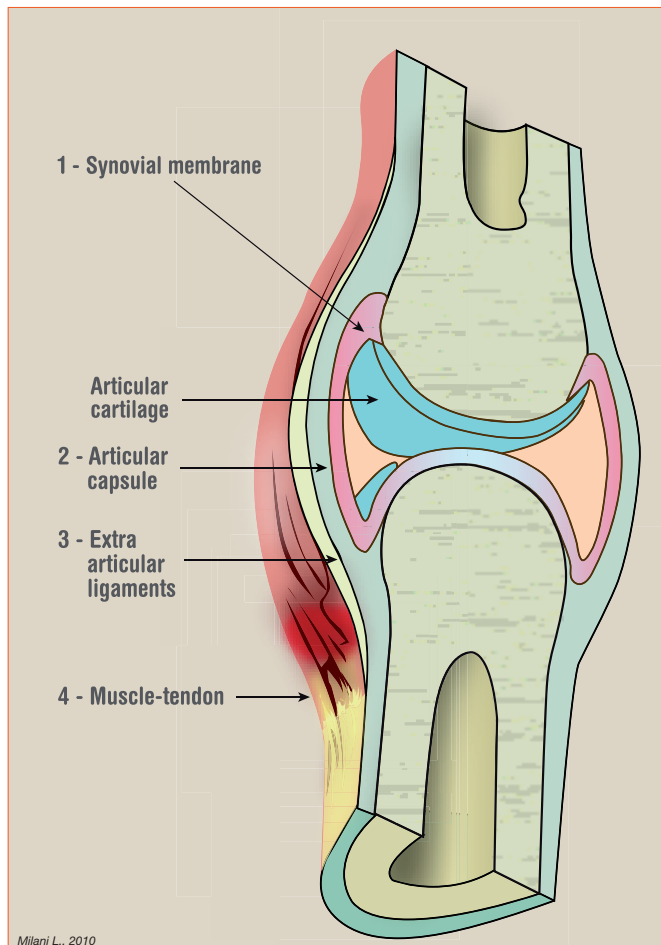
The study of Handson and Teller (2010) confirmed those of Garcia et Al., (1999) and Xu and Shen (2007).

– The effects of collagen administration (of different origin) in the prevention and therapy, are shown in TAB. 2 (author, 2010).

Trentham et Al., (1993) report successful results obtained with the administration of collagen in cases of active rheumatoid arthritis in a randomized, double-blind, placebo controlled trial carried out on a high number of cases (among which 4 complete resolutions), as well as the more recent trial by

FIG. 7

Extra-articular restraint apparatus.
- Four reinforcing overlapped structures (1, 2, 3, 4) cooperate with the good articular resistance, providing coaxial articular function or articular function according to the physiological slipping axes.



Milani L., 2010

Bagchi (2002) on non-rheumatoid arthritic diseases.

The use of hydroxyapatite-collagen nanocomposites (implants) has produced interesting results in serious deforming pathologies of the the cervical spine (Itoh *et Al.*, 2004).
 - However, the method is highly complicated and impractical as it involves fixing and removal interventions.

GUNA MEDICAL DEVICES FOR THE INJECTIVE TREATMENT OF DYSFUNCTIONAL AND PAINFUL ARTHRO MYOFASCIAL PATHOLOGIES

A new substantial and refined approach to the painful dysfunctional pathologies of the musculoskeletal system and of the related motor functions is now offered by **Guna Medical Devices** for use in clinical practice and in specialist facilities.

The **13 Guna Medical Devices (MD)** contain **collagen** and **ancillary substances of natural origin** (TAB. 3).

The ancillary substances allow a more effective and specific placement of collagen and have the function of conveying and stabilization.

► **Eight** of these MD are specific of the individual anatomical skeletal areas and of the disorders connected with them: **MD-NECK, MD-THORACIC, MD-LUMBAR, MD-SHOULDER, MD-HIP, MD-KNEE, MD-SMALL JOINTS, MD-POLY** (multi-articular)]; **one** is specific for the sciatic nerve [**MD-ISCHIAL**], and **four** others that are specific for tissue diseases, derived predominantly from mesodermal tissue: **MD-MUSCLE, MD-NEURAL, MD-MATRIX** (Extra Cellular Matrix), **MD-TISSUE** (soft tissues) (TAB. 3; FIG. 12).

All 13 Guna MD contain, in addition to the carrier excipient (ancillary), collagen of porcine origin.
 -The swine tissues have a **very high** average content of collagen (22.8% =

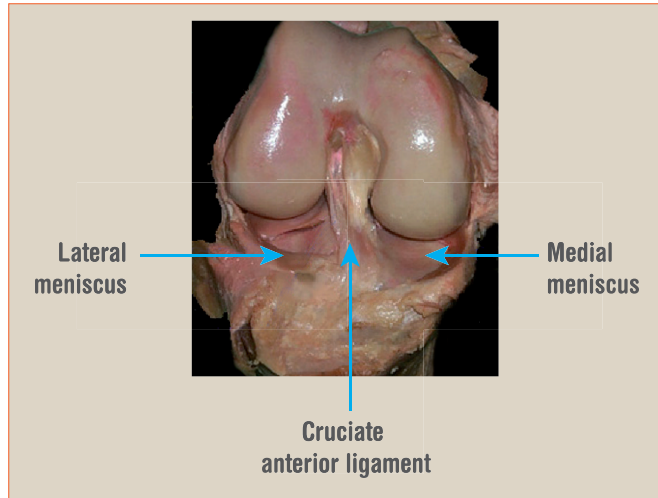


FIG. 8
Knee joint.
 - Intra-articular structures; the posterior cruciate ligament is not visible, the synovium is removed.

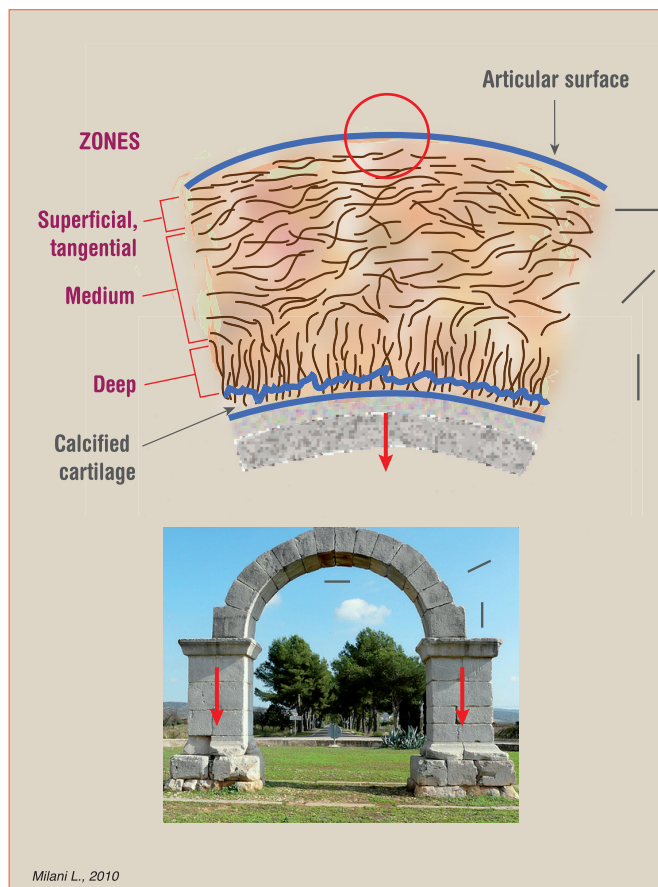


FIG. 9
a Schematic representation of the 3 different directions (superficial, medium, deep) of the collagen fibers in the articular cartilage.
b Structural equivalence between the orientations of the collagen fibers of the articular cartilage and the positioning of the stone blocks for the construction of a Romanesque arch (author, 2010).
 - The stone of the arch has its biological equivalent in the shorter length and larger thickening of collagen fibers in the area of maximum curvature of the cartilage (red circle).

Glycine, Proline = 13.8%; Hydroxy-Proline = 13%).

The average content of the other amino acids is only 3% (*max* Glutamic acid = 9.5%; *min* Tyrosine = 0.4%): the 50% is then made up of collagen.

Thanks to the particular process of tangential filtration, sterilization and control of molecular weight, a pure product (without contaminants) is obtained, that has the standard chemical and physical characteristics of a good and clinical safety.

The purpose of the local administration of this biomaterial “where it is needed” is structural: to replace, strengthen, structure and protect (adhesion barrier) the cartilage, the tendons, the ligaments, the joint capsules, etc.; to improve the structure of collagen fibers and - consequently - of all anatomical structures in which it is present; to provide mechanical support to the district concerned.

– One of the most important causes of district joint pain is the **laxity of the intra- and extra-articular stabilization**

structures; the loose restraint systems determine joint hypermobility, especially in not physiological directions and angles that wear and tear early the restraint systems themselves and act towards a progressive degeneration of the cartilage.

The **mechanical support** provided by the collagen is an effective natural support scaffold (bio-scaffold).

The infiltration of collagen and the single ancillary ingredients, is perfectly tolerated by the patient and devoid of adverse reactions. It is physiological, compatible and does not cause micro-inflammation with subsequent fibrotic retraction, as in prolotherapy, which covers basically the same purpose: the stabilization of periarticular structures.

– The proteoglycans (PGs) of the Extracellular Matrix (ECM) cementing the collagen fibers improve the viscoelastic properties of the endoarticular fluid, which does not happen in prolotherapy.

The loose musculoskeletal components and hypermobile joints stimulate local nociceptors and cause tension and excessive stress to localized areas. By reinforcing these areas, **regeneration** and **analgesic** effects occur.

The Guna MD improve physiological joint mobility, promote localized muscle distention, relieve localized pain or pain caused by joint movement or faulty posture.

Guna MD are **2ml injectable ampoules** for **subcutaneous, intradermal, periarticular, intraarticular and intramuscular** (local muscles) use.

► Guna MD can be used by themselves or along with in different associations (up to 2 ampoules per MD) according to the specific needs of the patient, or mixed with PRM injectable ampoules for Pain Therapy (ex. **MD-NECK + MD-MUSCLE + GUNA-NECK + GUNA-MUSCLE**) or as a complement to Homotoxicology (ex. Zeel T, Arnica comp.-Heel) or even conventional or local anesthetic injectable treatment.

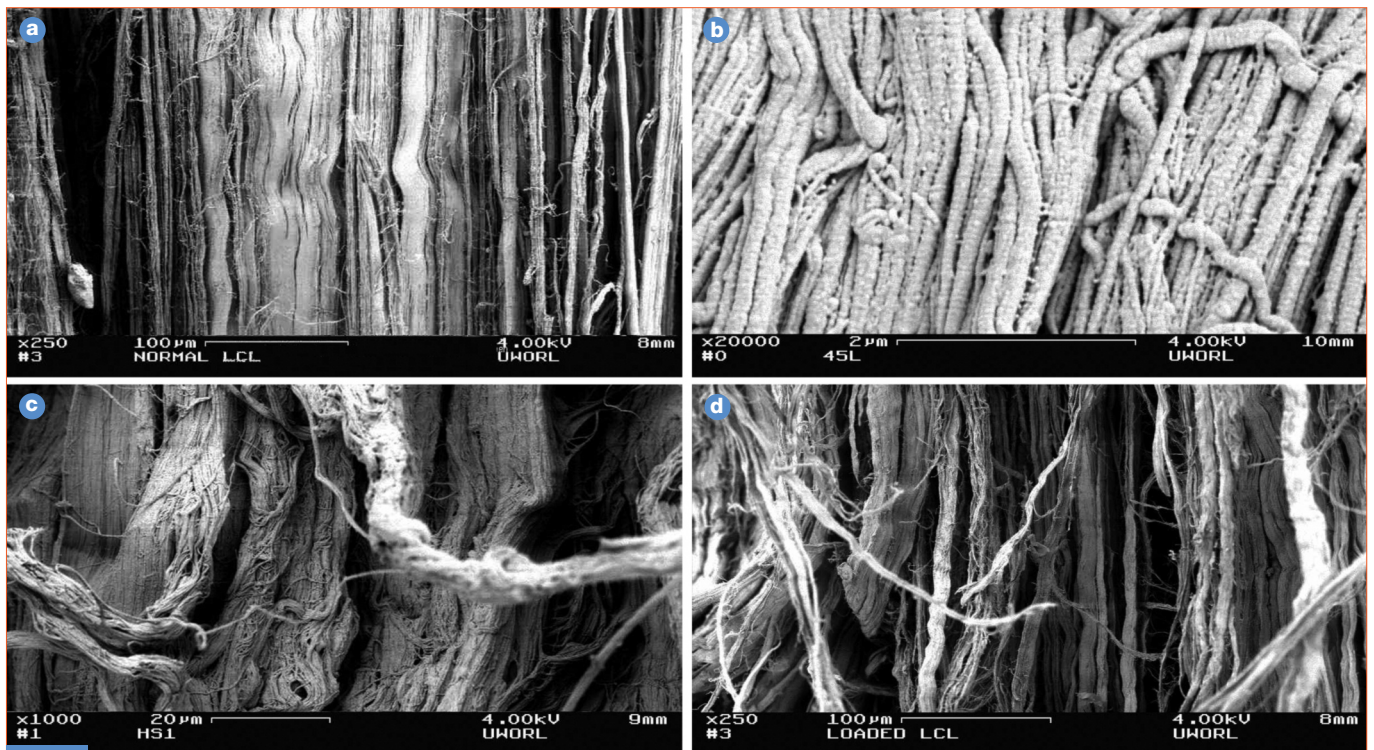


FIG. 10

Medial collateral ligament: a normal; b fork-fusion of collagen fibrils; c wound healing process; d microstructural damage due to overload (not breakage).

– Photomicrographs in P. Provenzano, Hurschler C., R. Vanderby Jr. - Connective Tissue Research, 42, 123-133, 2001.

Guna MD can also be used when the patient is treated with cortisone, NSAIDs and / or chondroprotective drugs without contraindications - and - as already mentioned - if the patient receives – during the treatment - manipulative therapy or other physical therapeutic methods (acupuncture, electroacupuncture, shiatsu, physiokinestherapy), instrumental methods (magnetic therapy, ultrasound, laser therapy, electrotherapy, etc.) or thermal therapy.

MAIN INDICATIONS OF GUNA MEDICAL DEVICES

MD-NECK

- Cervical pain secondary to cartilage degeneration of the cervical spine segments (cervical osteoarthritis) (in association with **MD-POLY**)
- Cervical pain secondary to muscle trigger point (in association with **MD-MUSCLE**)
- Stiff neck (in association with **MD-MUSCLE** and **MD-NEURAL**)
- Muscle tension cervical pain (in association with **MD-NEURAL** and **MD-MUSCLE**)
- Whiplash (in association with **MD-NEURAL** and **MD-MUSCLE**)
- Cervical pain due to postural defects (in association with **MD-NEURAL** and **MD-MUSCLE**)
- Alterations of the cervical axis (articular facet syndrome) (in association with **MD-NEURAL**)
- Cervical spinal ligaments syndrome (in association with **MD-NEURAL** and **MD-MATRIX**)
- Cervical radicular neuritis (in association with **MD-NEURAL**).

MD-THORACIC

- Back pain secondary to degenerative disorders of the cartilage of the dorsal spine segments (spinal osteoarthritis) (in association with **MD-POLY**)




FIG. 11
Photomicrographs (ME 3.000X) of muscle tissue of a fibromyalgic patients (left) and normal control (right).
– In the fibromyalgic tissue significant changes in the collagen structure can be observed (moth-eaten).

EFFECTS OF COLLAGEN ADMINISTRATION	
PREVENTION	
1 Inhibition of collagenesis	Author/s Chronological order Scutli, 1994 Walker, 1994 Wilson-Townsend, 1994 Kriegel, 1995
2 Inhibition of matrix metalloproteasis (MMPs)	Lee and Langer, 1983 Lee, 1984 Moses, 1990 Moses, 1993
THERAPY	
1 Wounds healing	Lansman et Al., 2009
2 Repair of Articular cartilage	Stone et Al., 1997 Cook et Al., 2006
3 Repair of tendons (acute and chronic pathologies)	Chenet et Al., 2007 Karaoglu et Al., 2007 Perry et Al., 2009
4 Repair of ligaments	Nijbizi et Al., 2000 Musahl et Al., 2006 Woo et Al., 2006 Liang et Al., 2006 Liang et Al., 2008

Milani L., 2010

TAB. 2

- Back pain secondary to scoliosis (in association with **MD-MUSCLE** and **MD-NEURAL**)
- Back pain secondary to trigger point of the dorsal muscles (in association with **MD-MUSCLE**)
- Pain secondary to osteophytosis of the dorsal spine (in association with **MD-NEURAL** and **MD-MATRIX**)
- Back pain secondary to osteoporosis (in association with **MD-NEURAL**, **MD-MUSCLE**, and **MD-TISSUE**)
- Alterations of the dorsal axis (articular spinal costal facet syndrome) (in association with **MD-NEURAL** and **MD-MATRIX**)
- Syndrome of spinal dorsal ligaments (in association with **MD-NEURAL**)
- Radicular neuritis of the dorsal spinal nerves (in association with **MD-NEURAL**).

TAB. 3

GUNA Medical Device		COMPOSITIONS
SPECIFIC LOCAL MDs	MD-NECK	Collagen + Silica
	MD-THORACIC	Collagen + <i>Cimicifuga racemosa</i>
	MD-LUMBAR	Collagen + <i>Hamamelis virginiana</i>
	MD-SHOULDER	Collagen + <i>Iris versicolor</i>
	MD-HIP	Collagen + Calcium phosphate
	MD-KNEE	Collagen + <i>Arnica montana</i>
	MD-SMALL JOINTS	Collagen + <i>Viola odorata</i>
	MD-POLY	Collagen + <i>Drosera rotundifolia</i>
SPECIFIC TISSUE MDs	MD-ISCHIAL	Collagen + <i>Rhododendron chrysanthum</i>
	MD-MUSCLE	Collagen + <i>Hypericum perforatum</i>
	MD-NEURAL	Collagen + <i>Citrullus colocynthis</i>
	MD-MATRIX	Collagen + Citric Acid, Nicotinamide
	MD-TISSUE	Collagen + Ascorbic Acid, Magnesium Gluconate, Pyridoxine chlorhydrate, Riboflavin, Thiamine chlorhydrate

MD-LUMBAR

- Low back pain secondary to lumbar cartilage degeneration (low back pain and lumbar osteoarthritis)
- Osteophytosis of the lumbar spine segments (in association with **MD-NEURAL** and **MD-MATRIX**)
- Low back pain secondary to muscle-tendon trigger points (in association with **MD-MUSCLE**)
- Low back pain from postural defects (in association with **MD-NEURAL**, **MD-MUSCLE**, and **MD-TISSUE**)
- Mechanical alterations of the lumbar and lumbosacral axis (in association with **MD-NEURAL**)
- Syndrome of lumbar and lumbosacral spinal ligaments (in association with **MD-MATRIX**)
- Sacroiliac joint syndrome (in association with **MD-NEURAL**)
- Radicular neuritis of the lumbar and lumbosacral spinal nerves (in association with **MD-NEURAL** and **MD-ISCHIAL**).

MD-SHOULDER

- Humero-scapular peri arthritis (in association with **MD-POLY**)
- Rotator cuff syndrome (in associa-

tion with **MD-MUSCLE** and **MD-TISSUE**)

- Shoulder-arm syndrome (in association with **MD-NEURAL** and **MD-MUSCLE**)
- Frozen shoulder (in association with **MD-MUSCLE**)
- Shoulder pain secondary to dislocation (pre-therapy and post-reduction, in association with **MD-NEURAL**)
- Epicondylitis (in association with **MD-NEURAL** and **MD-POLY**).

MD-HIP

- Coxarthrosis
- Inflammation of the hip joint capsule (in association with **MD-MATRIX**)
- Coxarthrosis in case of rheumatoid arthritis (in association with **MD-POLY**)
- Coxalgia of muscular origin (in association with **MD-MUSCLE**)
- Coxalgia of nervous origin (burning hip) (in association with **MD-NEURAL**)
- Coxalgia due to prolonged bed rest (in association with **MD-MATRIX** and **MD-TISSUE**).

MD-KNEE

- Gonarthrosis (in association with **MD-POLY**)
- Knee pain secondary to rheumatoid arthritis or other autoimmune diseases (in association with **MD-POLY**)
- Acute and chronic arthrosynovitis secondary to trauma, arthrosis and rheumatoid arthritis (in combination with **MD-POLY**)
- Arthrosynovitis post-traumatic and post-surgical acute and chronic
- Traumatic injuries or collateral ligament of the knee
- Meniscus pain (in association with **MD-POLY**)
- Preparation of meniscectomy surgery (in association with **MD-MUSCLE**)
- Maintenance therapy after knee surgery (in association with **MD-MUSCLE-NEURAL**).

MD-SMALL JOINTS

- Osteoarthritis of the hand fingers
- Rhizoarthrosis of the thumb (Forestier's disease)
- Arthralgia caused bunion
- Carpal tunnel syndrome (in associ-

ation with **MD-NEURAL**)

- De Quervain’s disease (in association with **MD-NEURAL**)
- Simple metatarsalgia
- Metatarsalgia associated with Morton’s neuroma (in association with **MD-NEURAL**)
- Rheumatoid arthritis of the hand and foot (in association with **MD-POLY**)
- Hand and foot tendinopathy secondary to prolonged immobilization (in association with **MD-MATRIX**).

MD-ISCHIAL

- Sciatica
- Lumbar-sciatic pain (in association with **MD-LUMBAR** and **MD-NEURAL**)
- Lumbar neuralgia (in association with **MD-MUSCLE**)
- Sciatica after surgery for herniated disc L4-L5, L5-S1 (in association with **MD-NEURAL**)
- Morton’s neuroma (in association with **MD-NEURAL**).

MD-POLY

- Nonspecific diffuse pain (in association with **MD-NECK** or **MD-THORACIC** or **MD-LUMBAR**, and **MD-NEURAL**)
- Costal sternal syndrome (in association with **MD-NEURAL**)
- Chronic polyarthritis secondary to autoimmune disease (eg, Systemic Lupus Erythematosus) (if the neuralgic symptoms prevail: in association with **MD-NEURAL**; if muscle symptoms prevail: in association with **MD-MUSCLE**)
- Syndrome of “the broken bones” (if the neuralgic symptoms prevail: in association with **MD-NEURAL**; if muscle symptoms prevail: in association with **MD-MUSCLE**)
- Joint pain secondary to viral disease (in association with other specific Guna MD)
- Joint pain secondary to cancer (eg, chronic leukemia, multiple myeloma) (in association with other specific district Guna MD).

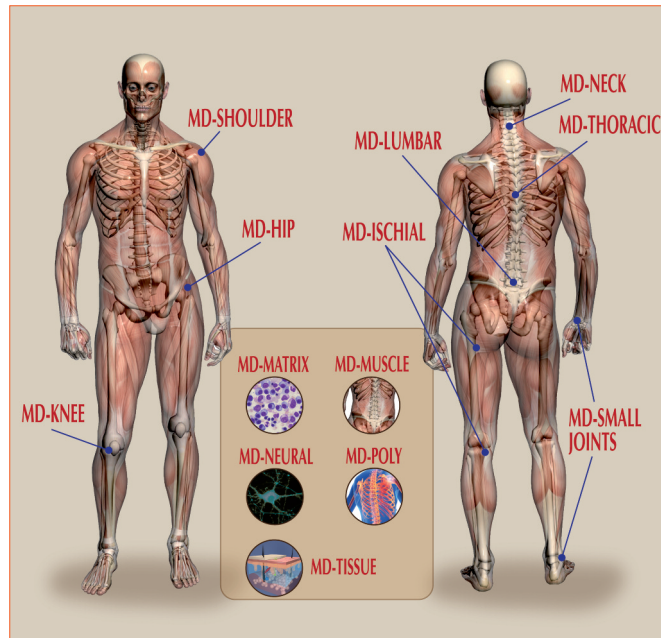


FIG. 12

Synopsis of the 13 injectable Guna Medical Devices.

MD-MUSCLE

- Treatment of acute, subacute, chronic myofascial pain
- Treatment of trigger points (in association with **MD-NEURAL**)
- Treatment of referred pain areas (in association with **MD-NEURAL**)
- Fibromyalgia (in association with **MD-NEURAL** and **MD-MATRIX**)
- Dermatomyositis.

MD-NEURAL

- Brachial nerve neuralgia secondary to cervical entrapment syndrome (in association with **MD-NECK**)
- Persistent intercostal neuralgia (in association with **MD-THORACIC**)
- Postherpetic neuralgia (in association with **MD-THORACIC** or **MD-LUMBAR**)
- Atypical facial neuralgia (in association with **MD-NECK** and **MD-TISSUE**)
- Trigeminal neuralgia (in association with **MD-NECK** and **MD-MATRIX**)
- Pain of the temporomandibular joint (in association with **MD-NECK**)
- Radicular neuritis of the cervical dorsal, lumbar, sacral spinal nerves, (respectively in association with **MD-NECK**, **MD-THORACIC**, **MD-LUMBAR**, and **MD-ISCHIAL**).

MD-MATRIX

MD-MATRIX can be used alone or combined with any other MD of the same line, in order to create a personalized treatment based on the individual clinical picture.

► **MD-MATRIX can also be used in patients who need anti-aging topical treatment.**

MD-TISSUE

Also MD-TISSUE may be used alone or combined with any other MD of the same line, according to the individual clinical picture.

► **MD-TISSUE can also be used in patients who need anti-aging topical treatment.**

CONCLUSIONS

With increasing age (Mays *et Al.*, 1988), physical inactivity, intense physical activity or inadequate sports activity (Adam *et Al.*, 1984), postural alterations, nutrient imbalances, changes of the PNEI axis, the connective tissue and the collagen in particular (real tissue protein) gradually dete-

riorate and become inadequate at fulfilling their many specific functions.

– The possibility to use in the praxis specific injections of **Medical Devices** (distinct and tissue MD) that replace the collagen deficiency always detectable in inflammatory and/or degenerative diseases of the locomotor apparatus and of other structures of mesodermal origin, injections that are easy to apply, natural, with no negative side effects, that can be associated with PRM (Physiological Regulating Medicine) therapies or homotoxicological or conventional local or systemic injective therapies in progress or planned and/or any physical therapy, provides an innovative and sophisticated tool for the prevention and treatment of the aging process of intra-articular and periarticular structures as well as structures of the nearby mesodermal support tissues.

– The non-invasiveness of the injections with Guna MD, the first ones in this field having reported therapeutic results in 7 controlled clinical trials (Registration report at the High Institute of Health - Italy), as well as their other characteristics such as efficacy, tolerability, absence of allergic and natural reactions, makes this a unique and valuable tool in the specialistic and non specialistic praxis in improving the quality of life of patients who were intended - otherwise - to get worse or become chronic. ■

References

including the items shown in Figures and Tables

1. Adam M. et Al. – Degenerated annulus fibrosus of the intervertebral disc contains collagen type II. *Ann Rheum Dis*, **1984** Apr; 43(2): 258-263.
2. Amprino R. – Studi sul significato meccanico delle fibrille collagene della cartilagine ialina dell'uomo. *Ricerche descrittive e sperimentali in individui di varia età*. Eingenangen Ann. 15 Sept., **1938**.
3. Athenstedt H. – Pyroelectric and piezoelectric properties of vertebrates. *Ann NY Acad Sci.*, **1974**; 238: 68-110.
4. Bagchi D. – Effects of orally administrated undenaturated type II collagen against arthritic inflammatory diseases. A mechanistic exploration. *Int. J. of Clin. Pharmacol. Research*, **2002**, Vol 22, 3-4; 101-10.
5. Bergsmann O., Bergsmann R. –

Projektions Symptome - Reflektorische Krankheitszeichen als Grundlage für holistische Diagnose und Therapie. 2. Aufl. Wien: Facultas; **1997**.

6. Bozel L. et Al. – Collagen fibrils: nanoscale ropes. *Biophys. J.* 9,7; **2007**.
7. Burgeson R.E. et Al. – Collagen types. Molecular structure and tissue distribution. *Clin. Anthropol Relat Res.*, **1992** Sept; (282): 250-272.
8. Chen J.M. et Al. – Autologous tenocyte therapy using porcine derived bioscaffolds for massive rotator cuff defect in rabbit. *Journal of Bone and Joint Surgery*. British Volume, Vol 91-8, Issue SUPP II, 346, **2009**.
9. Cinseros D. et Al. – Observing growth steps of collagen self-assembly by time-lapse high-resolution atomic force microscopy. *J. of Structural Biol.*, 154, 232 (**2006**).
10. Cook J.L. et Al. – Long-term outcome for large meniscal defects treated with small intestine submucosa in a dog model. *Am. J. Sports Med.*, Jan 1, **2006**; 34(1): 32-42.
11. Garcia L. et Al. – Suppression of collagen-induced arthritis by oral or nasal administration of type II collagen. *J Autoimmun* **1999**; 13: 315-24.
12. Gronemann S.T. et Al. – Collagen and muscle pathology in fibromyalgia patients. *Rheumatology* **2004**; 43: 27-31.
13. Handson F., Teller Z. – A Placebo Controlled Study of Collagen Hydrolysate in Subjects with Knee Osteoarthritis (in press), **2010**.
14. Heine H., Andrà F. – Meccanismo d'azione antinfiammatoria di un farmaco omotossicologico composto (titolo tradotto). *Arzzeitung für Naturheilverfahren*, **2002**, 2.
15. Heine H. – *Manuale di Medicina Biologica. Regolazione di base e matrice extracellulare*. 3a Edition. Guna Ed., Milano; **2009**.
16. Hodge A., Petruska J. – A submit model for the tropocollagen macromolecule. *Proc. Natl. Acad. Sci.* 51, 871-885; **1964**.
17. Itoh S. et Al. – Development of a hydroxyapatite/collagen nanocomposite as a medical device. *Cell Transplant.* **2004**; 13(4): 451-61.
18. Jan Y. et Al. – A mitochondrial protein, Bit 1, mediates apoptosis regulated by integrins and Groucho/TLE corepressors. *Cell* 116, 751-762; **2004**.
19. Jiang F. et Al. – Assembly of collagen into microribbons: effects of pH and electrolytes. *J. of Structural Biol.*, 148, 268 (**2009**).
20. Karaoglu S. et Al. – Use of a bioscaffold to improve healing of a patellar tendon defect after graft harvest for ACL reconstruction: A study in rabbits. *Journal of Orthopaedic Research*, Vol 26, Issue 2; 255-263, **2007**.
21. Kastelic J. et Al. – The multicomposite structure of tendon. *Connective Tissue Research*, **1978**, Vol 6, pp.11-23.
22. Landsman A. et Al. – The role of Collagen Bioscaffolds, Foamed collagen and Living Skin Equivalents in Wound Healing. *Clinics in Pediatric Medicine and Surgery*, Vol 26, Issue 4; 525-533, **2009**.
23. Liang R. et Al. – Long-term effects of porcine small intestine submucosa on the healing of medial collateral ligament: a functional tissue engineering study. *Journal of Orthopaedic Research*, Vol 24; Issue 4; 811-19, **2006**.
24. Liang R. et Al. – Effects of a bioscaffold on collagen fibrillogenesis in healing medial collateral ligament in rabbit. *Journal of Orthopaedic Research*, Vol 26, Issue 8; 1098-1104, **2008**.
25. Lima de Faria A. – *Evoluzione senza selezione*. Nova Scripta Ed., **2003**.
26. Lynsenmeyer T.F. – Collagen. In: Hay ED (Ed); *Cell Biology of Extracellular matrix*. 2nd ed., New York and London: Plenum; **1991**; 7-44.
27. Mackey A.L. et Al. – Changes in human muscle collagen content following exercise. *Muscle Res Cell Motil*, **2002**; 23-9.
28. Mays P.K. et Al. – Age-related changes in the proportion of types I and III collagens. *Mech Ageing Dev*, **1988**, Nov 30, 45(3); 203-212.
29. Milani L. – *Terapia dell'invecchiamento della matrice: la ricarica dell'orologio biologico*. La Med. Biol., **2004**/4; 17-25 (a).
30. Milani L. – *Weihe e altri Punti. Tra Agopuntura e Omeopatia*. Libro-Atlante. Guna Ed., **2004** (b).
31. Milani L. – *Prefazione a Manuale di Medicina Biologica. Regolazione di base e matrice extracellulare*. 3a Edition Guna Ed., Milano; **2009**.
32. Milani L. – *Lezioni di Omeosiniatria. Dispensa (CD) della Scuola Triennale di Omeopatia, Omotossicologia e Discipline Integrate; Anno accademico 2010-2011 – III Anno*.
33. Musahl V. et Al. – The use of porcine small intestine submucosa to enhance the healing of the medial collateral ligament. A functional tissue engineering study in rabbits. *Journal of Orthopaedic Research*, Vol 22, Issue 1; 214-20, **2006**.
34. Niyibizi C. et Al. – Type V collagen is increased during rabbit medial collateral ligament healing. *Knee Surgery, Sports Traumatology, Arthroscopy*, Vol 8, 5/Sept, **2000**.
35. Olsen B.R. – Collagen Biosynthesis. In: Hay ED (Ed); *Cell Biology of Extracellular matrix*. 2nd ed., New York and London: Plenum; **1983**: 139-178.
36. Ozaki J. et Al. – Tears of the rotator cuff of the shoulder associated with pathological changes in the acromion. A study in cadavera. *J Bone Joint Surg Am.*, **1988** Sept, 70(8), 1224-30.
37. Perry S. et Al. – Use of small intestine submucosa in a rat model of acute and chronic rotator cuff tear. *Journal of Shoulder and Elbow Surgery*, Vol 16, Issue 5; 179-183, **2009**.
38. Pfaff M. et Al. – Integrin and Arg – Gly – Asp dependence of cell adhesion to the native and unfolded triple helix of collagen type VI. *Exp. Cell Res.*, 206, 167-176; **1993**.
39. Pischinger A. – *Das System der Grundregulation. Grundlagen für eine ganzheitsbiologische Theorie für Medizin*. 4. Aufl. Heidelberg. Hang, **1983**.
40. Prockop D.J. – Artificial sweeteners - enhancing glycosylation to treat muscular dystrophies. *N. Engl. J. Med.*, **2004**, 351: 1236-1254.
41. Provenzano P.P. et Al. – Microstructure morphology in the transition region between sear and intact residual segments of a healing at medial collateral ligament. *Connect. Tiss. Research*, 42; 123-133; **2001**.
42. Riley G.P. et Al. – Tendon degeneration and chronic shoulder pain: changes in the collagen composition of the human rotator cuff tendons in rotator cuff tendinitis. *Annals of the Rheumatic Diseases*, **1994**; 53: 359-366.
43. Rizzuto R. – The collagen mitochondria connection. *Nat. Genet.* 35, 300-1; **2003**.
44. Savolainen J. et Al. – Effect of immobilization on collagen synthesis in rat skeletal muscles. *Am. J Physiol*, **1987**; 252: 883-8.
45. Stone K.M. et Al. – Regeneration of meniscal cartilage with the use of a collagen scaffold. Analysis of preliminary data. *The Journal of Bone and Joint Surgery*, 79 1170-7, **1997**.
46. Trentham D.E. et Al. – Autoimmunity to type II collagen. An experimental model of arthritis. *JEM*, 164(3); 857, **1977**.
47. Trentham D.E. et Al. – Effects of oral administration of type II collagen on rheumatoid arthritis. *Science*, Vol 261, Issue 5129, 1727-30; **1993**.
48. Van der Rest M. et Al. – Collagen family of proteins. *FASEB J.*, **1991** Oct 5 (13): 2814-2823.
49. Woo S.L. et Al. – Treatment with bioscaffold enhances the fibril morphology and the collagen composition of healing medial collateral ligament in rabbits. *Tissue Eng.*, **2006** Jan; 12(1): 158-166.
50. Xu D., Shen W. – Chicken collagen type II reduces articular cartilage destruction in a model of osteoarthritis in rats. *West Ind Med J*, Vol. 56, 3; June **2007**.
51. Yunus M.B. et Al. – Pathologic changes in muscle in primary fibromyalgia syndrome. *Am J Med*, **1986**; 81 (Suppl. 3A): 38-42.

Textbooks

1. Abrahams L. – Histology. Zigler & Baum, Fort Lauderdale – Florida (USA); **2008**.
2. Guna Medical Device. Guna Ed., **2010**.
3. International Advisory Committee (Coordinatore L. Milani) – Omeopatia-Omotossicologia. Le prove scientifiche dell'efficacia. Quinta edizione riveduta e aggiornata. Guna Ed., **2010**.

Recommended readings

1. Milani L. – Omeosiniatria e trigger miofasciali: un'accoppiata vincente. La Med. Biol., 2003/2; 31-41 (Parte Prima); La Med. Biol., **2003/3**; 29-41 (Parte Seconda).
2. Silver T. – Joint and Soft Tissue Injection – Injecting with confidence. Fourth Edition. Radcliffe Publishing, Oxford (UK), **2007**.

The author sincerely thanks

Hippokrates Verlag and Guna Editore for the reproduction of the images in **Figs. 1** (amended), **3, 5** (only 1, 2) from H. Heine - Manuale di Medicina Biologica. Regolazione di base e matrice extracellulare. 3rd edition, completely revised, **2009**, and the Editors of the websites from which the images were taken:

Figure 2 (only on the top):

http://farm1.static.flickr.com/160/405756871_794fca5e86.jpg

Fig. 6: http://www.helmholtz-muenchen.de/uploads/pics/fig4-2_textmedium.png

Fig. 10:

a: <http://silver.neep.wisc.edu/~lakes/slideTissue.dir/LigFig3.jpg>

b: <http://silver.neep.wisc.edu/~lakes/slideTissue.dir/LigFig4A.jpg>

c: <http://silver.neep.wisc.edu/~lakes/slideTissue.dir/LigFig2.jpg>

d: <http://silver.neep.wisc.edu/~lakes/slideTissue.dir/LigFig4B.jpg>

Fig. 11: <http://rheumatology.oxfordjournals.org/cgi/content/ful/43/1/27>

Figs. **2, 4** (amended), **5, 7, 9** and Tab. **1, 2, 3** belong to the author.

Text developed, expanded and updated from the lectures held by the author at the 26th Annual Conference of the American Association of Orthopaedic Medicine (AAOM) Palm Springs (CA), USA, April 25th, 2009, the 33rd National Congress of the Italian Association for the Study of Pain (AISD), Section New Frontiers of Pain Medicine, Florence, May 24, 2010 and the 3rd Italian Congress S.I.P.O. Rome, October 15-16, 2010.

author's address**Leonello Milani, MD, PhD**

- Vice President of the *International Academy of Physiological Regulating Medicine*
- Vice President A.I.O.T.
- Scientific Director of La Medicina Biologica and of *Physiological Regulating Medicine*

Via Palmanova, 71
I – 20132 Milano